

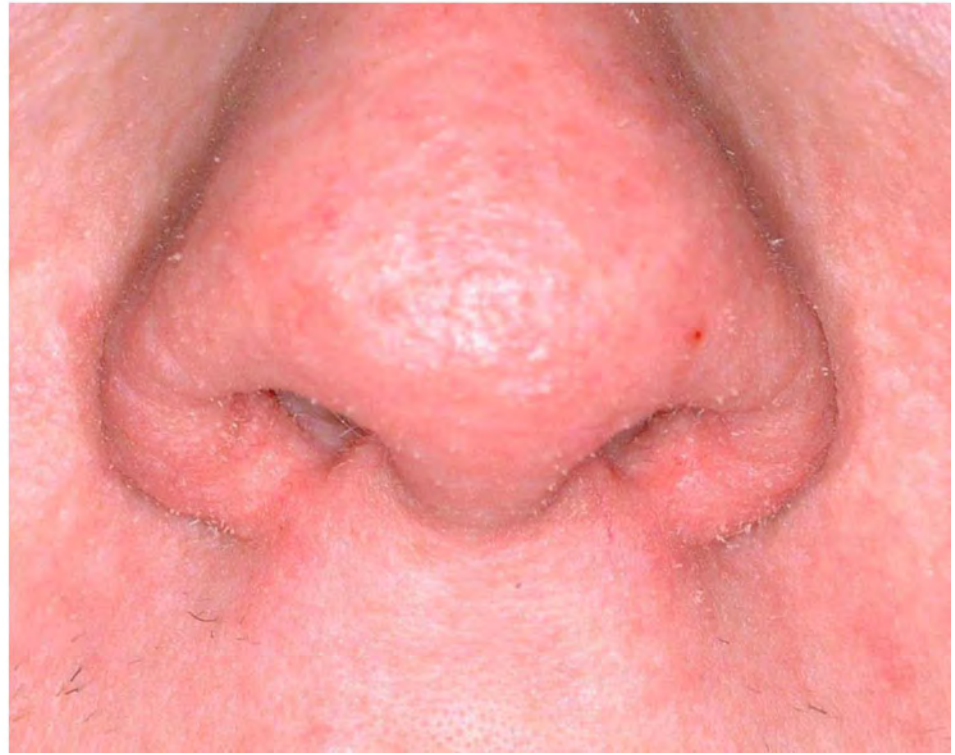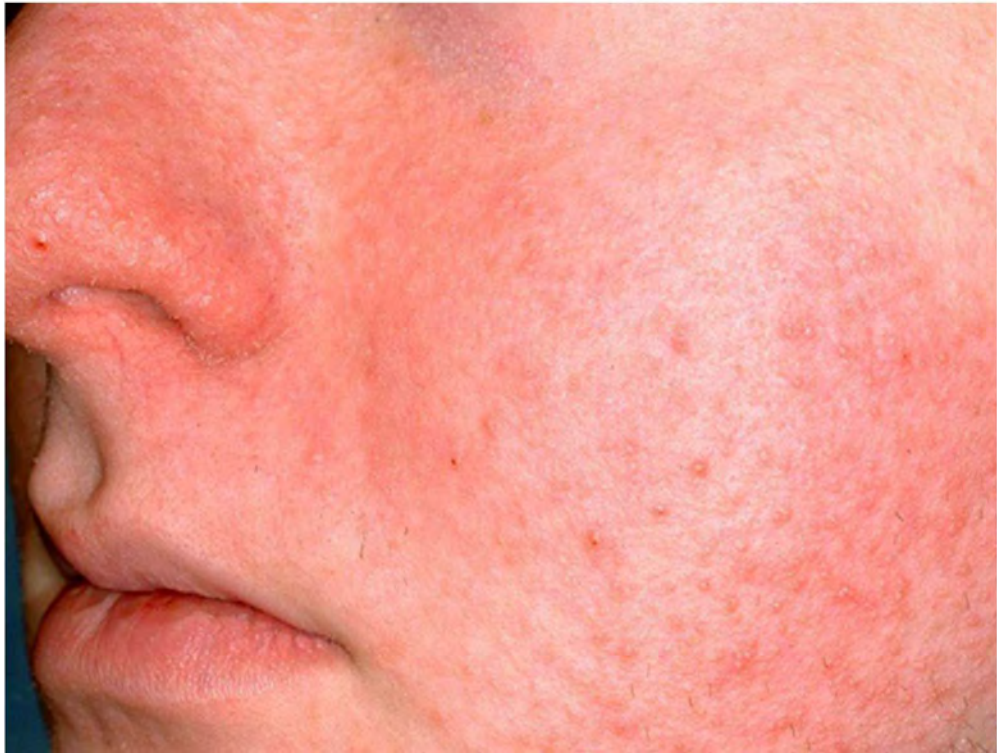Graz, July 2, 2025

Instructive Cases from NY

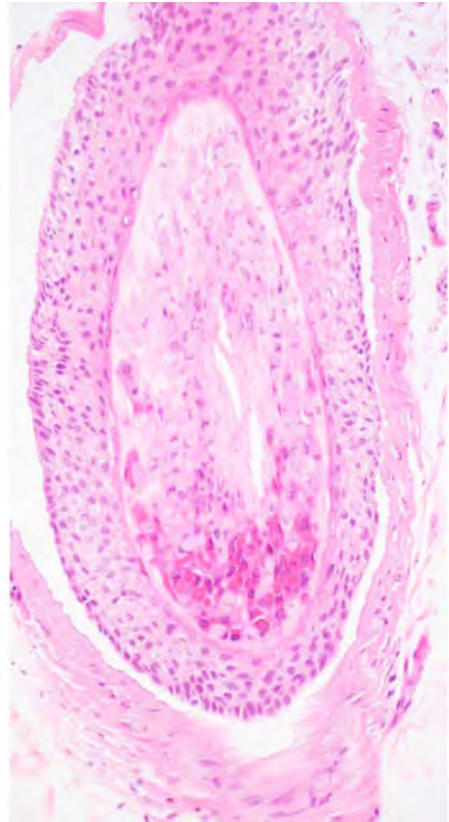
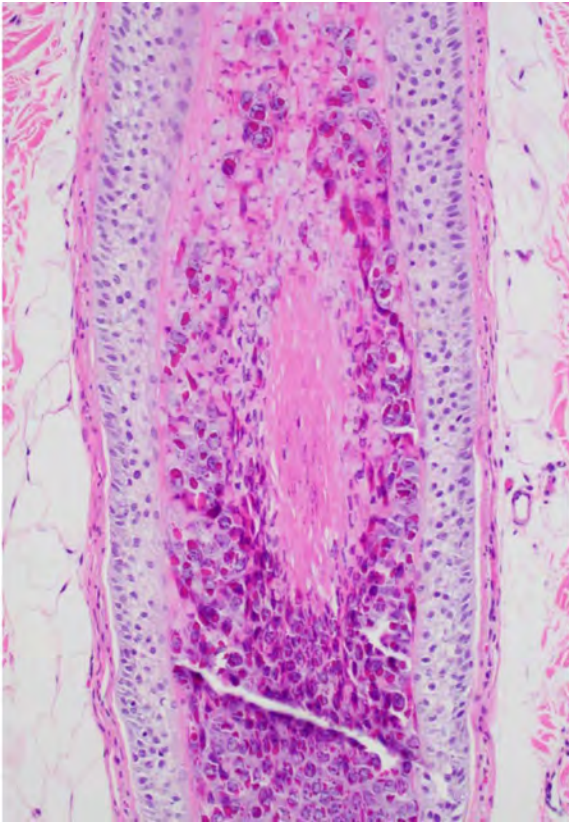
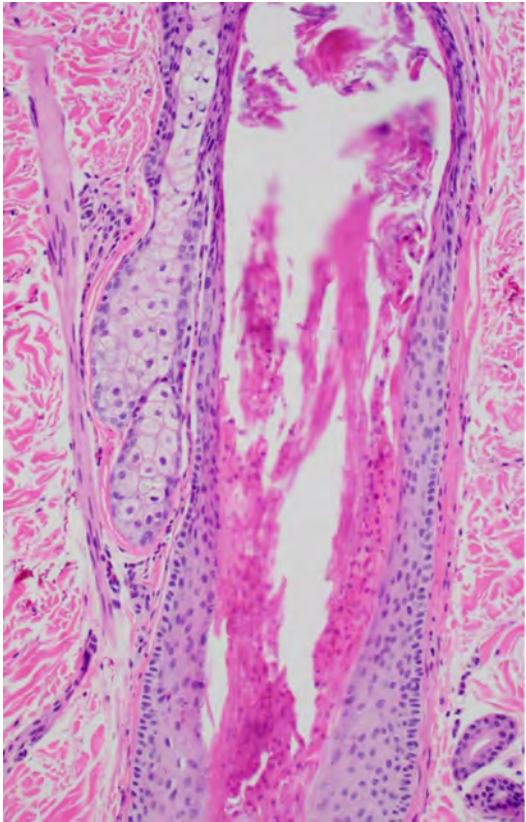
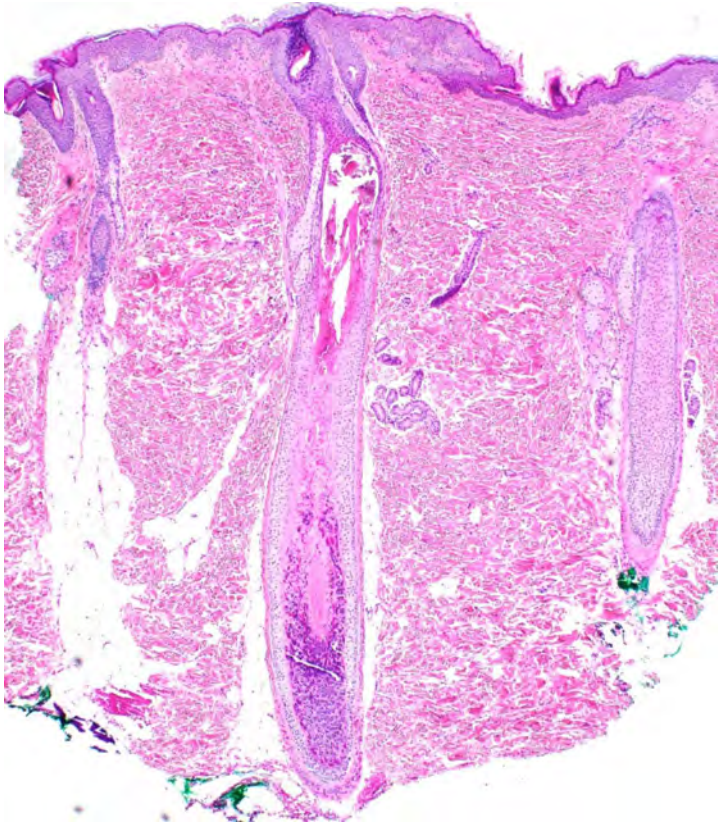
Klaus J Busam, MD

Memorial Sloan Kettering Cancer Center

Case 1: h/o pre-B-ALL s/p chemo

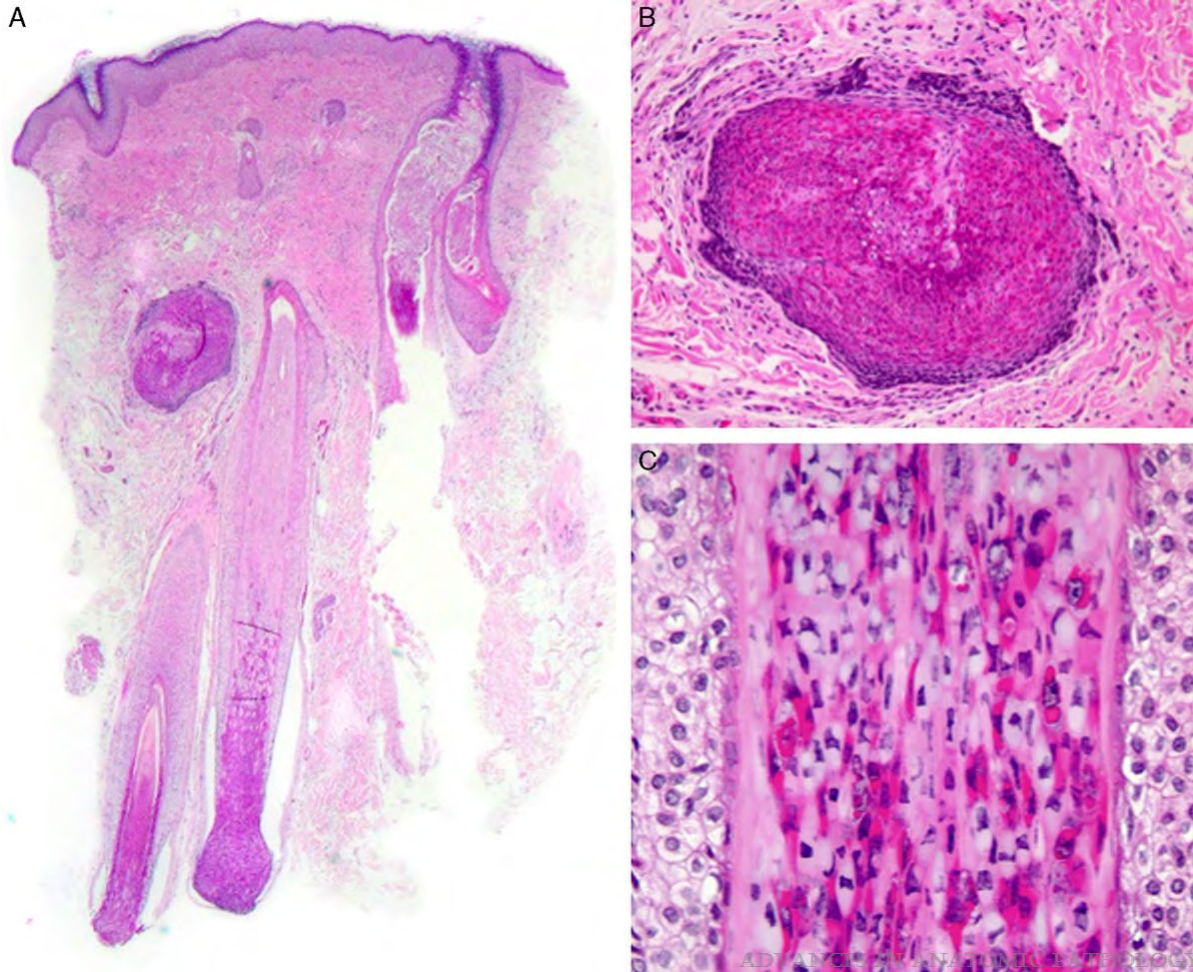


Case 1: Histopathology



Expanded Inner Root Sheath

Case 1: Trichodysplasia Spinulosa



- **Virus-associated Trichodysplasia Spinulosa**

- Tan, Belinda H.; Busam, Klaus J.

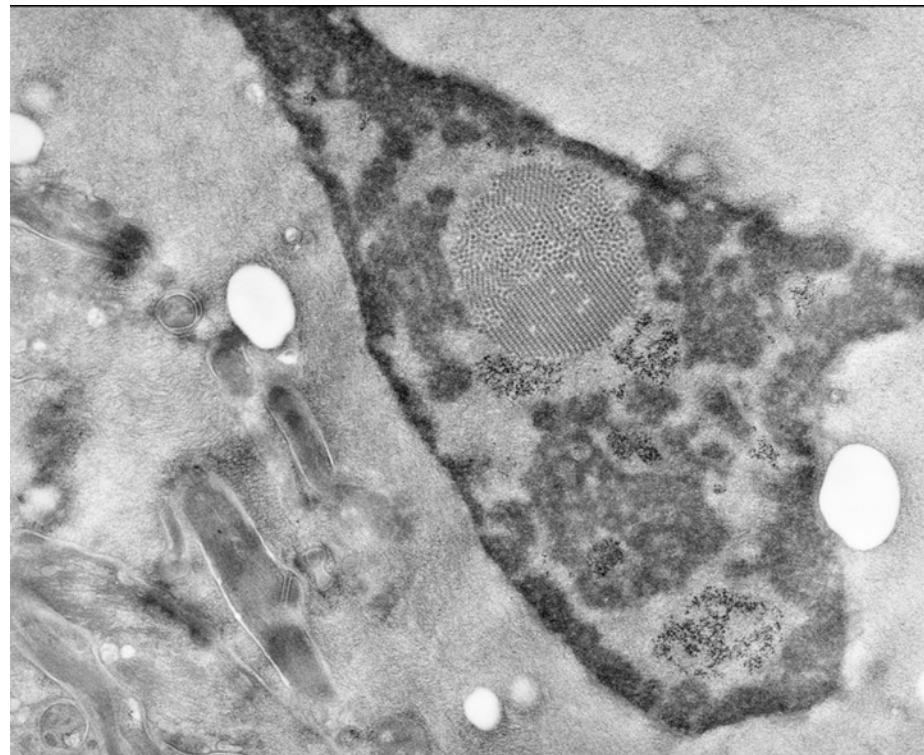
- Advances in Anatomic Pathology 18(6):450-453, November 2011.

- A: Abnormal anagen hair follicles.
- B: Follicle with abundant inner root sheath cells surrounded by a thin rim of germinative basophilic cells.
- C: Trichohyaline-rich granules of the inner root sheath.

Virus-Associated Trichodysplasia Spinulosa

Angela J. Wyatt, MD, Dana L. Sachs, MD,† Jinru Shia, MD,‡
Ruby Delgado, MD,‡ and Klaus J. Busam, MD,‡*

Am J Surg Pathol 2005; 29: 241 – 6.



[Hair-like hyperkeratoses in patients with kidney transplants. A new cyclosporin side-effect]

[Article in German]

J Izakovic ¹, S A Büchner, M Düggelin, R Guggenheim, P H Itin

CASE REPORTS

Cyclosporine-induced folliculodystrophy

Michael R. Heaphy, Jr, MD,^a H. Nicholas Shamma, MD,^b Martha Hickmann, MD,^c
and Michael J. White, MD^a
Dayton, Ohio

We describe a 34-year-old kidney transplant patient who developed a distinct cutaneous side-effect to cyclosporine manifested as an infiltrated appearance to the skin with abundant flesh-colored, follicular papules predominantly affecting the ears, nose, and surrounding areas of the face, but also the trunk and extremities. The clinical and histologic findings in this case closely match those presented in 2 previous case reports, in which immunosuppressive doses of cyclosporine appeared to be causative. We present a detailed report of the clinical and histologic findings that are unique to these 3 cases and we introduce a theory, based on the recent in vitro studies involving cyclosporine, to help explain the pathogenic events induced by cyclosporine in these patients. We propose the term "cyclosporine induced folliculodystrophy" or CIF as an appropriate name for this distinct clinicohistopathologic entity. Finally, we set forth 3 clinical and 4 histopathologic criteria upon which the diagnosis of CIF can be made. (J Am Acad Dermatol 2004; 50:310-5.)

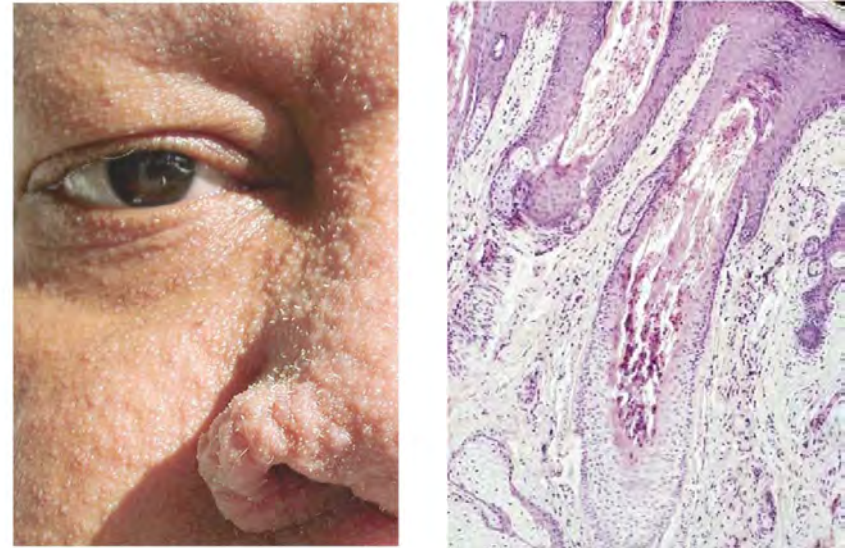
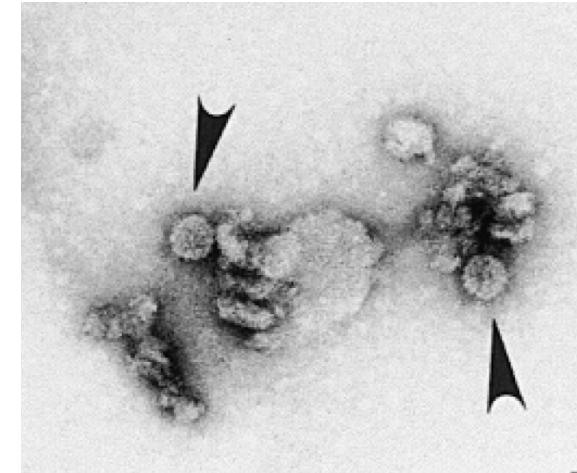
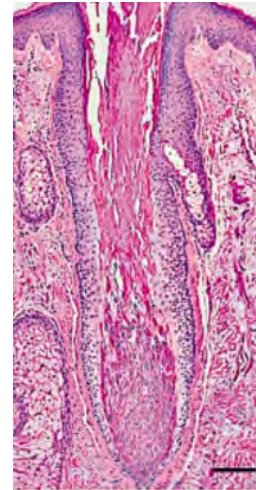
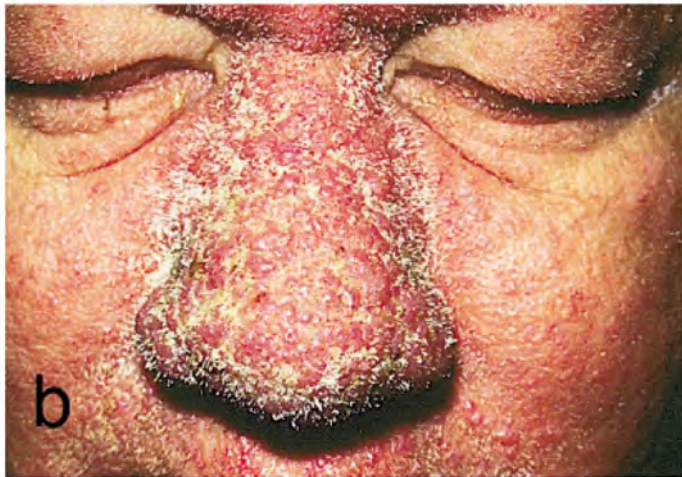

Fig 1. Flesh-colored, follicular papules located predominantly on the nose and surrounding areas of the face.

Trichodysplasia Spinulosa – A Newly Described Folliculocentric Viral Infection in an Immunocompromised Host

Claire L. Haycox, Susan Kim, Philip Fleckman, Lynne T. Smith, Michael Piepkorn, John P. Sundberg,*
David N. Howell,† and Sara E. Miller‡

Department of Medicine (Dermatology), University of Washington, Seattle, Washington, U.S.A.; *The Jackson Laboratory, Bar Harbor, Maine, U.S.A.; †Departments of Pathology, Duke University Medical Center & Veterans Affairs Medical Centers, Durham, North Carolina, U.S.A.; ‡Departments of Microbiology and Pathology, Duke University Medical Center, Durham, North Carolina, U.S.A.



44M with D, s/p combined renal and pancreas transplant

Identification of TSV

OPEN ACCESS Freely available online PLoS Pathog. 2010 Jul 29;6(7):e1001024. PLoS PATHOGENS

Discovery of a New Human Polyomavirus Associated with *Trichodysplasia Spinulosa* in an Immunocompromized Patient

Els van der Meijden¹, René W. A. Janssens², Chris Lauber¹, Jan Nico Bouwes Bavinck³, Alexander E. Gorbalenya¹, Mariet C. W. Feltkamp^{1*}

¹Department of Medical Microbiology, Leiden University Medical Center, Leiden, The Netherlands, ²Department of Dermatology, Jeroen Bosch Hospital, 's-Hertogenbosch, The Netherlands, ³Department of Dermatology, Leiden University Medical Center, Leiden, The Netherlands

> J Clin Virol. 2012 Mar;53(3):225-30. doi: 10.1016/j.jcv.2011.11.007. Epub 2011 Dec 22.

Trichodysplasia spinulosa is characterized by active polyomavirus infection

Simaque Kazem¹, Els van der Meijden, Sander Kooijman, Arlene S Rosenberg, Lauren C Hughey, John C Browning, Genevieve Sadler, Klaus Busam, Elena Pope, Taylor Benoit, Philip Fleckman, Esther de Vries, Just A Eekhof, Mariet C W Feltkamp

Affiliations + expand

PMID: 22196870 DOI: 10.1016/j.jcv.2011.11.007

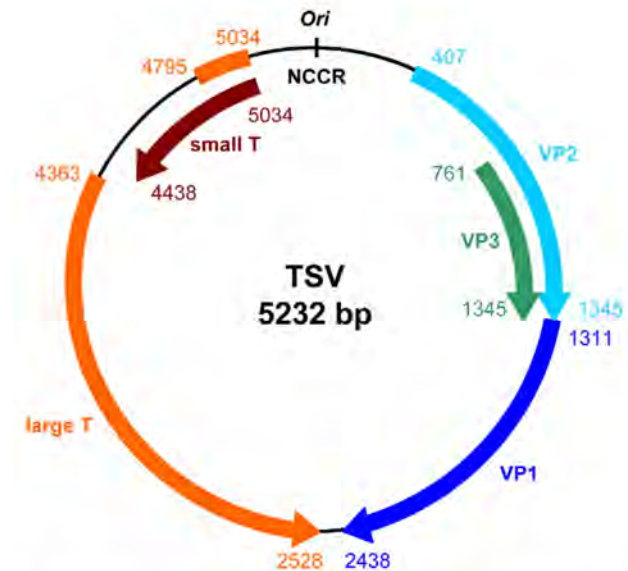
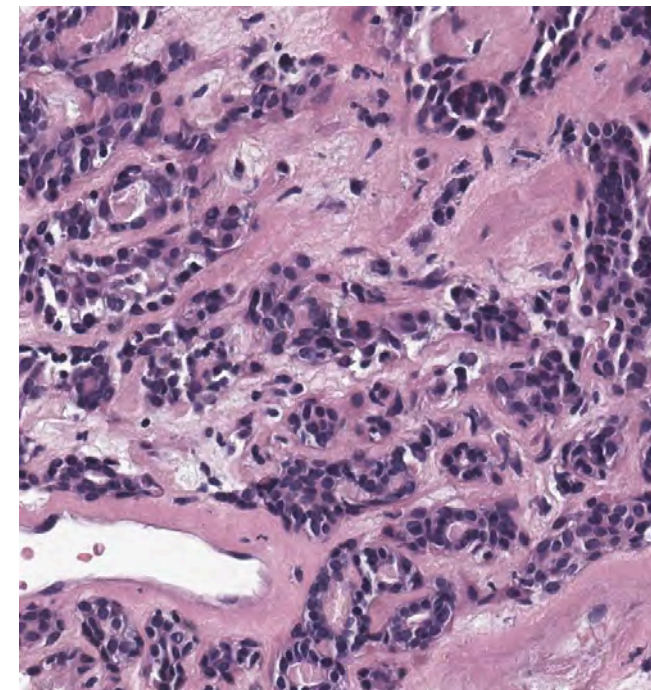
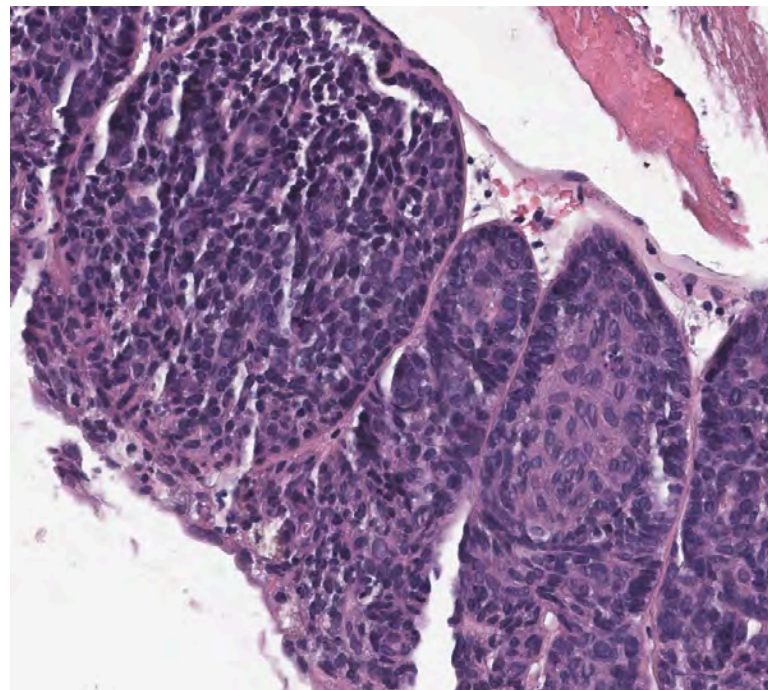
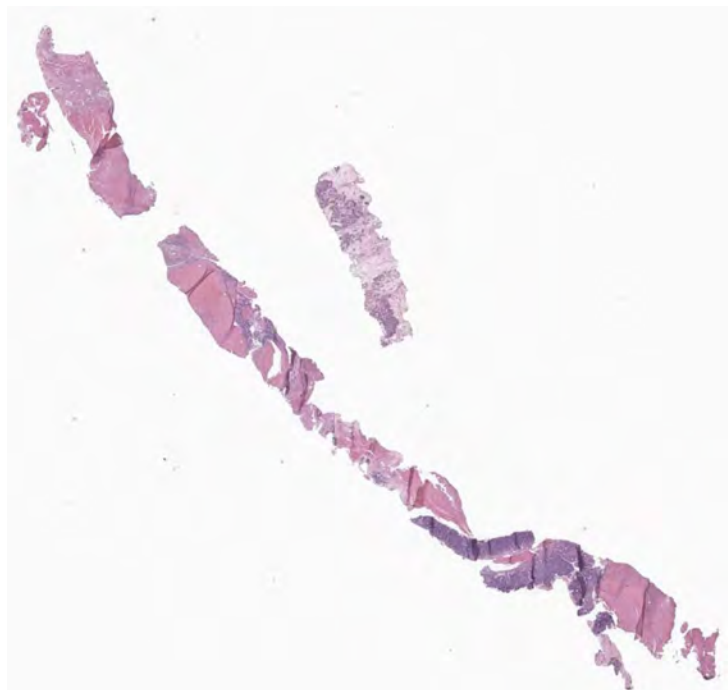


Figure 3. Genome map of TSV. Indicated are the five identified ORF representing the putative “early” genes encoding small and large antigen, and the putative “late” genes encoding VP1, VP2 and VP3. The NCCR is placed on top and contains the putative ori. Nucleotide position 1 was chosen within the NCCR in the large T binding region. For a detailed view of the NCCR, see Figure 4A. doi:10.1371/journal.ppat.1001024.g003

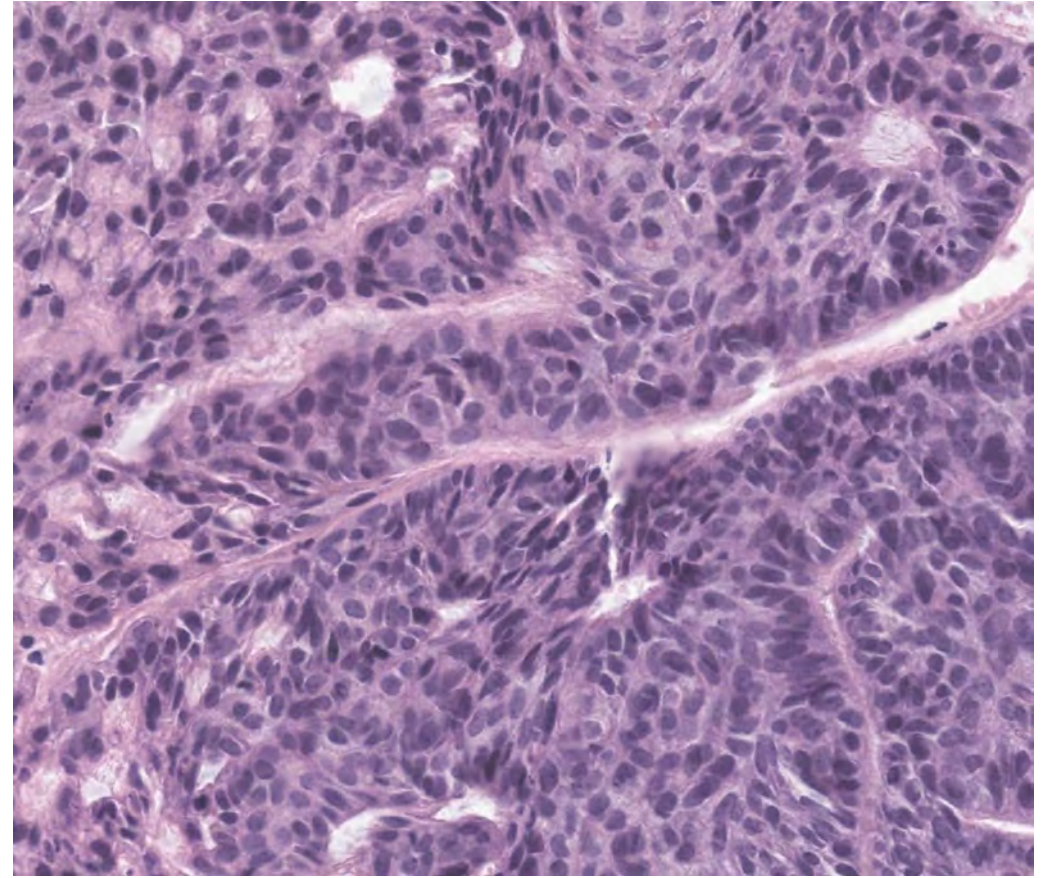
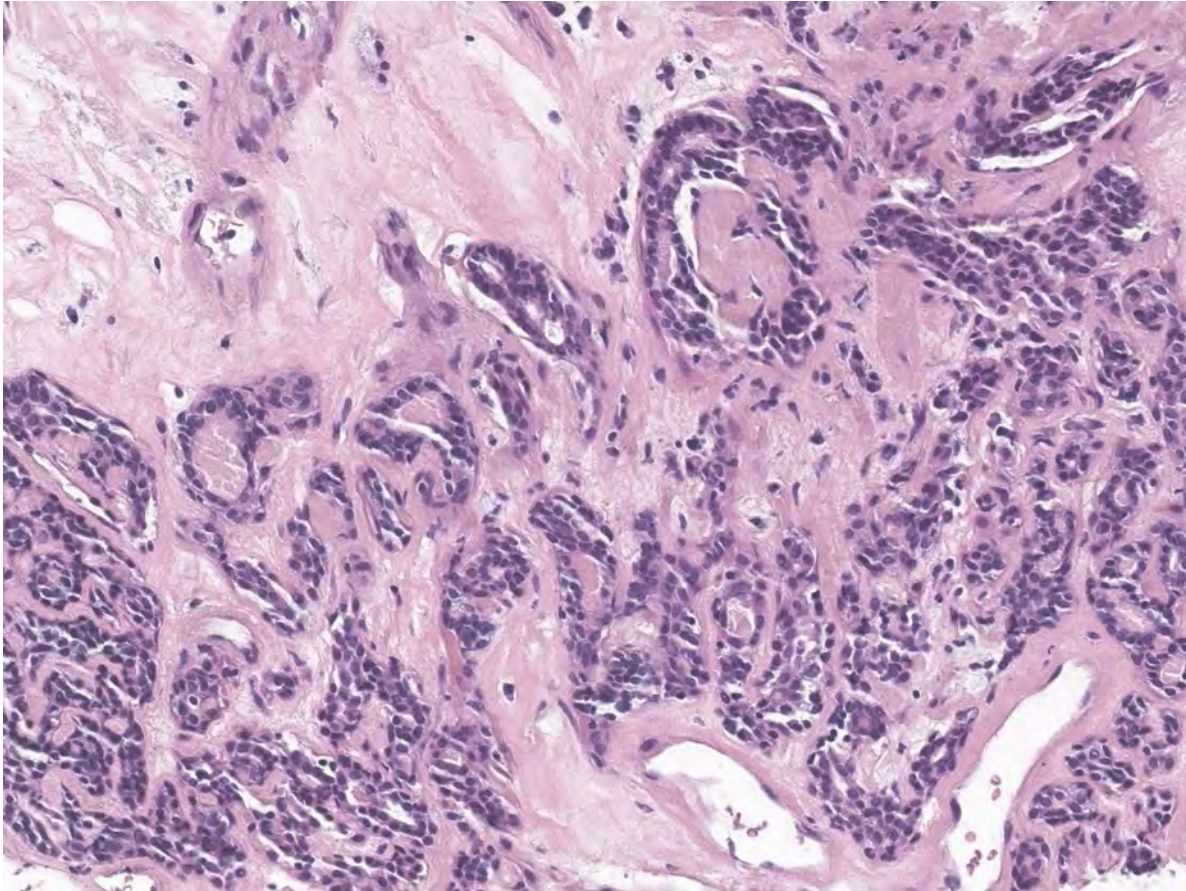
Lessons from case 1:

- Trichodysplasia spinulosa is a virus-associated rash
- It is associated with distinct clinical and pathologic findings
 - Clinical: Follicular spicules
 - Pathology: Excessive inner root sheath formation

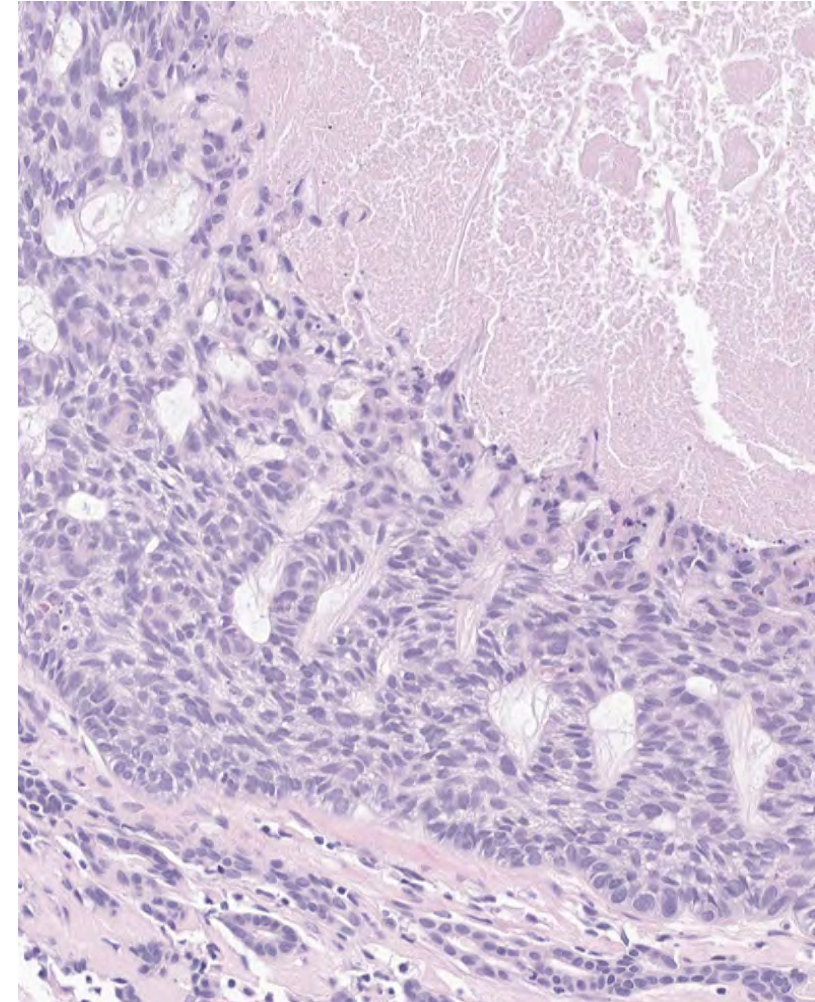
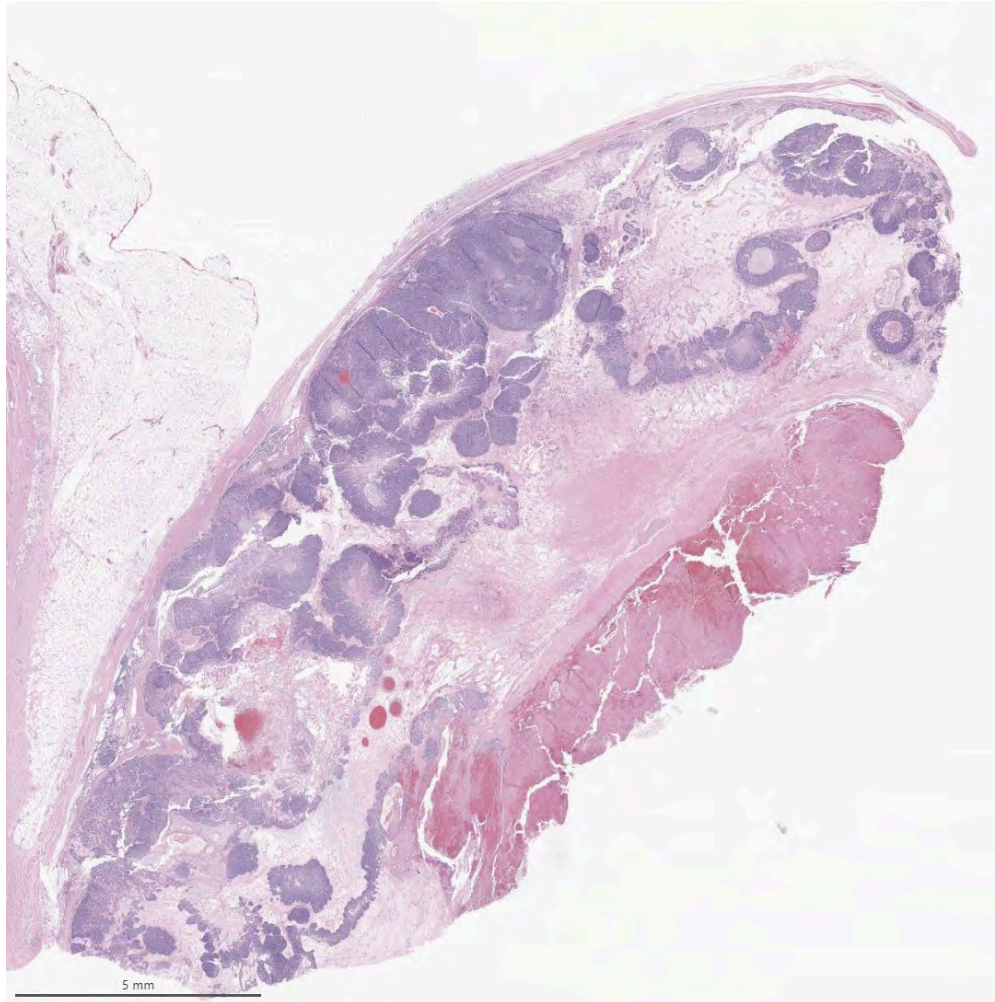
Case 2: 76 M with axillary mass - biopsy



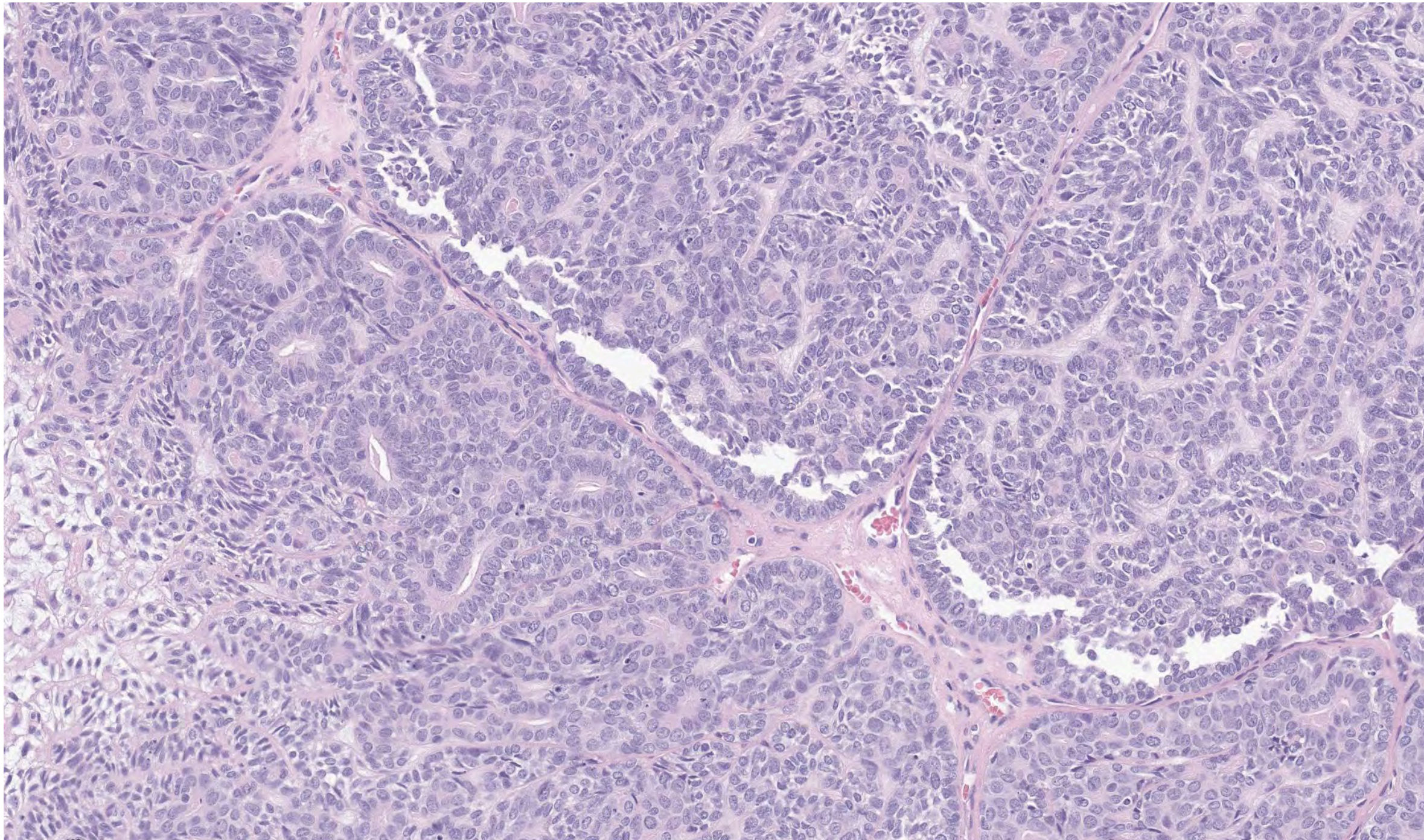
Case 2: Histopathology

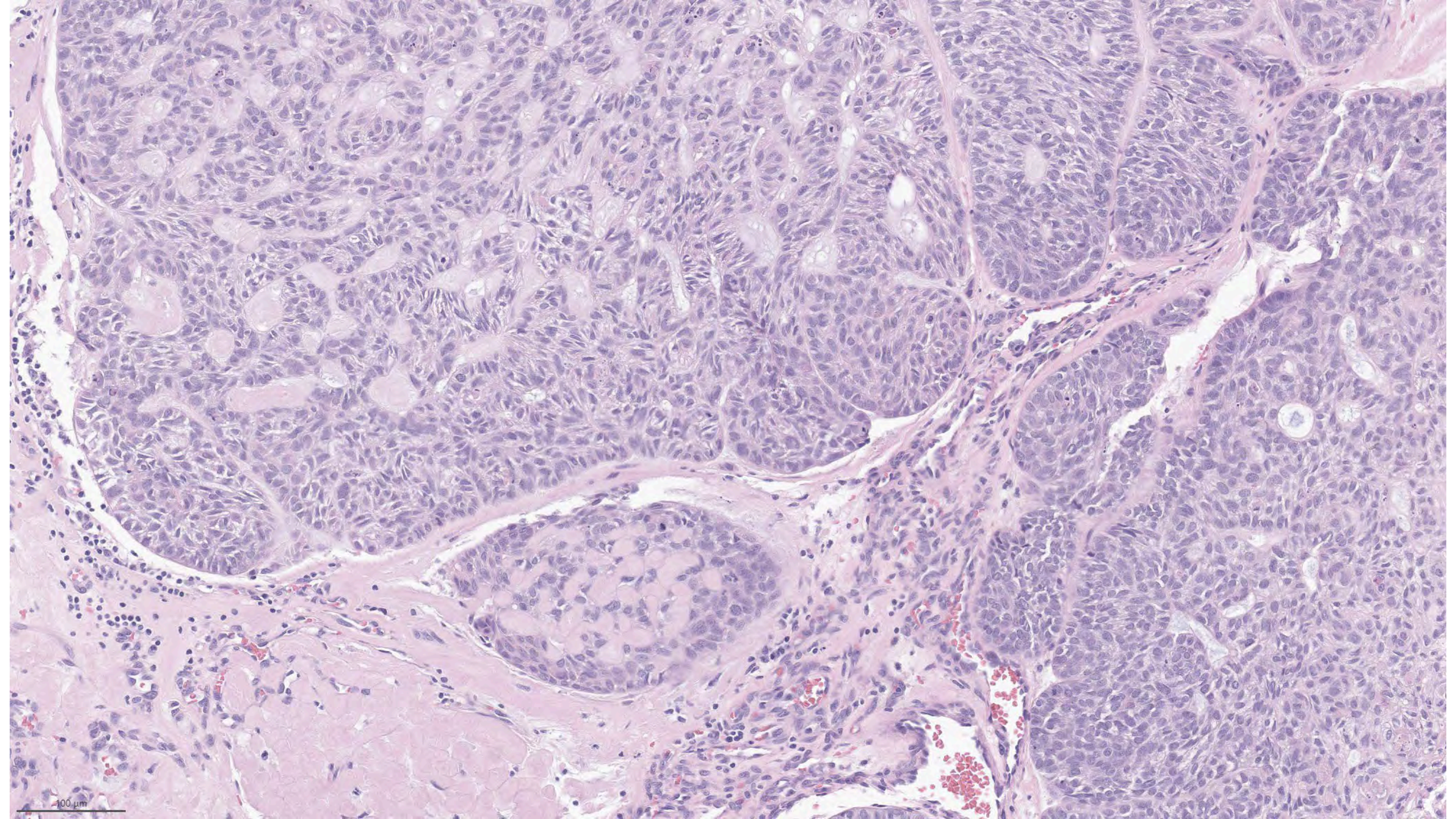


Excision



76 M with axillary mass



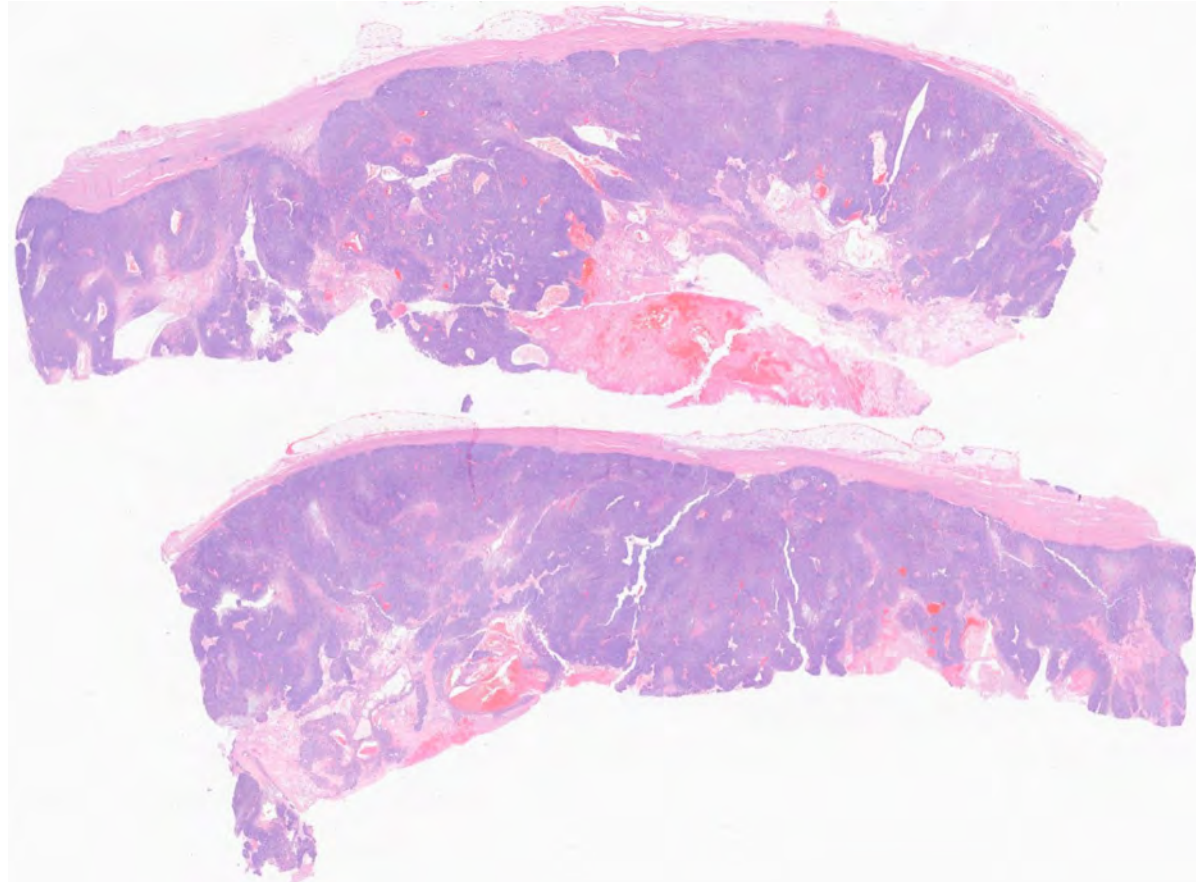


What is Your Diagnosis?

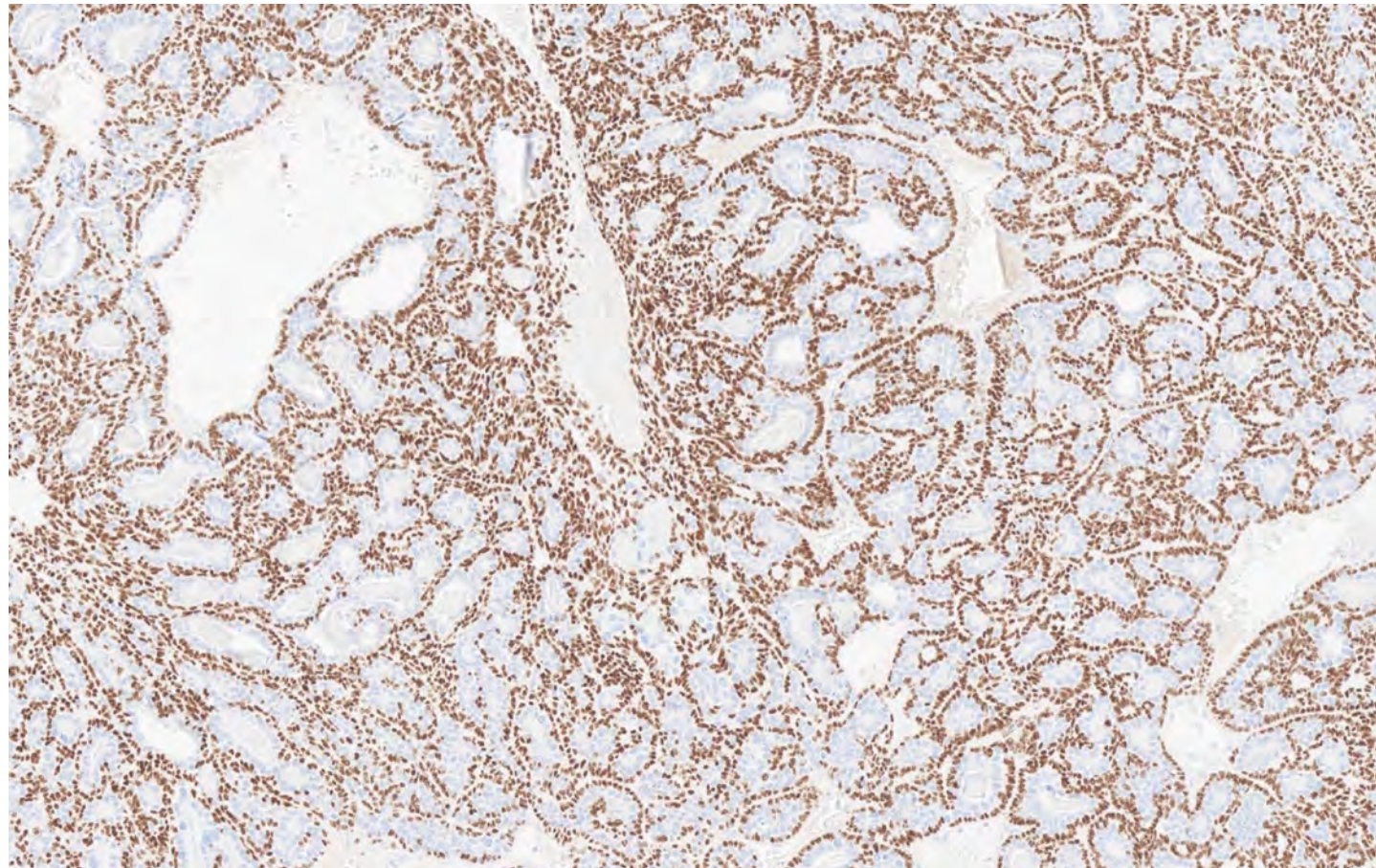
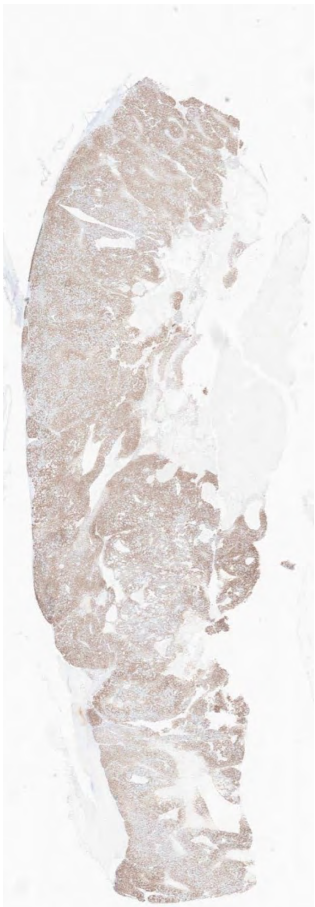
- 76M
- Axillary Mass

Differential:

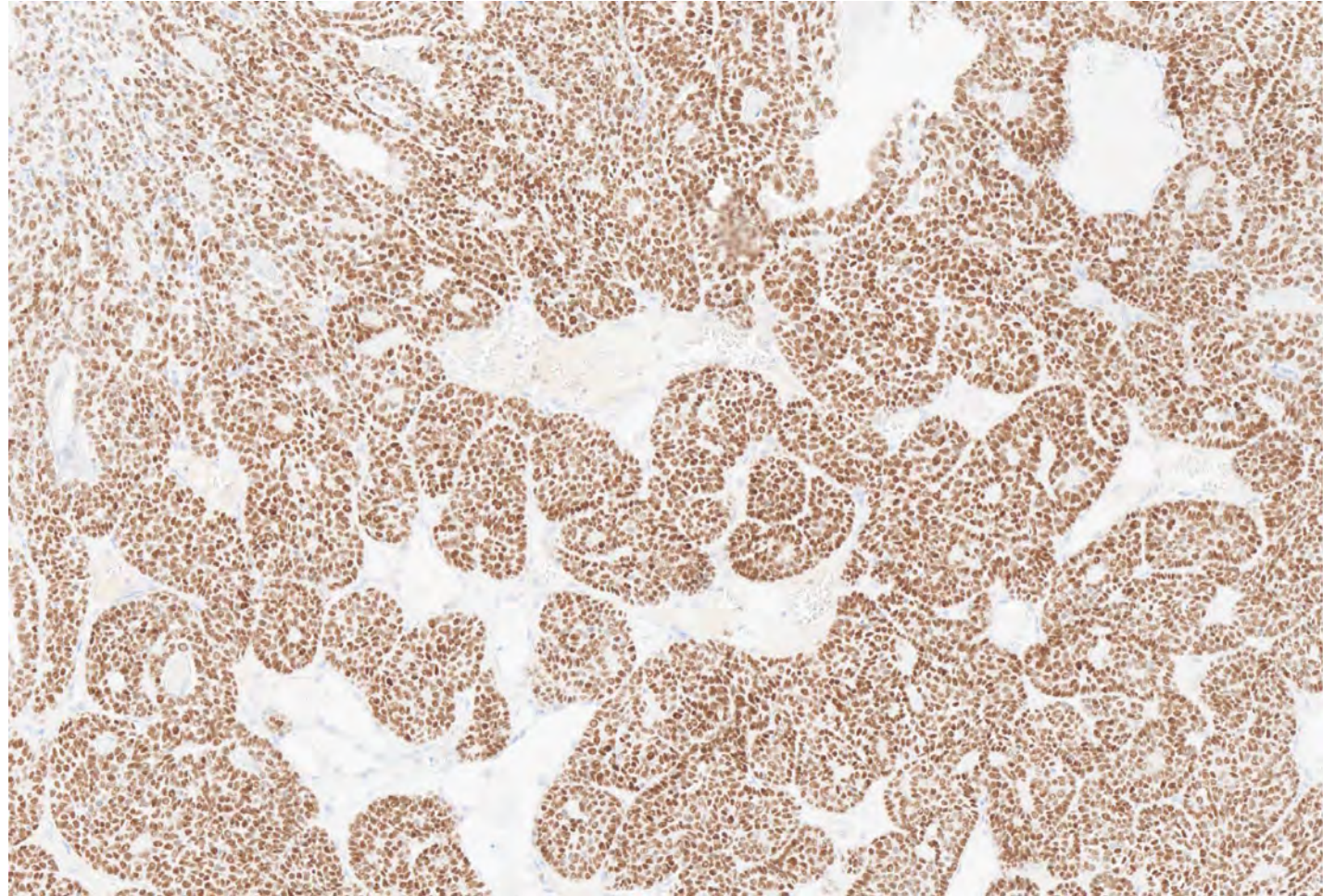
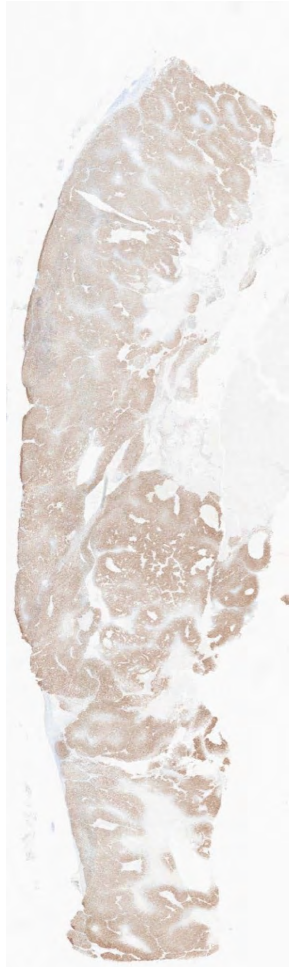- Adenoid cystic carcinoma
- Spiradenocarcinoma
- Other



IHC for p63



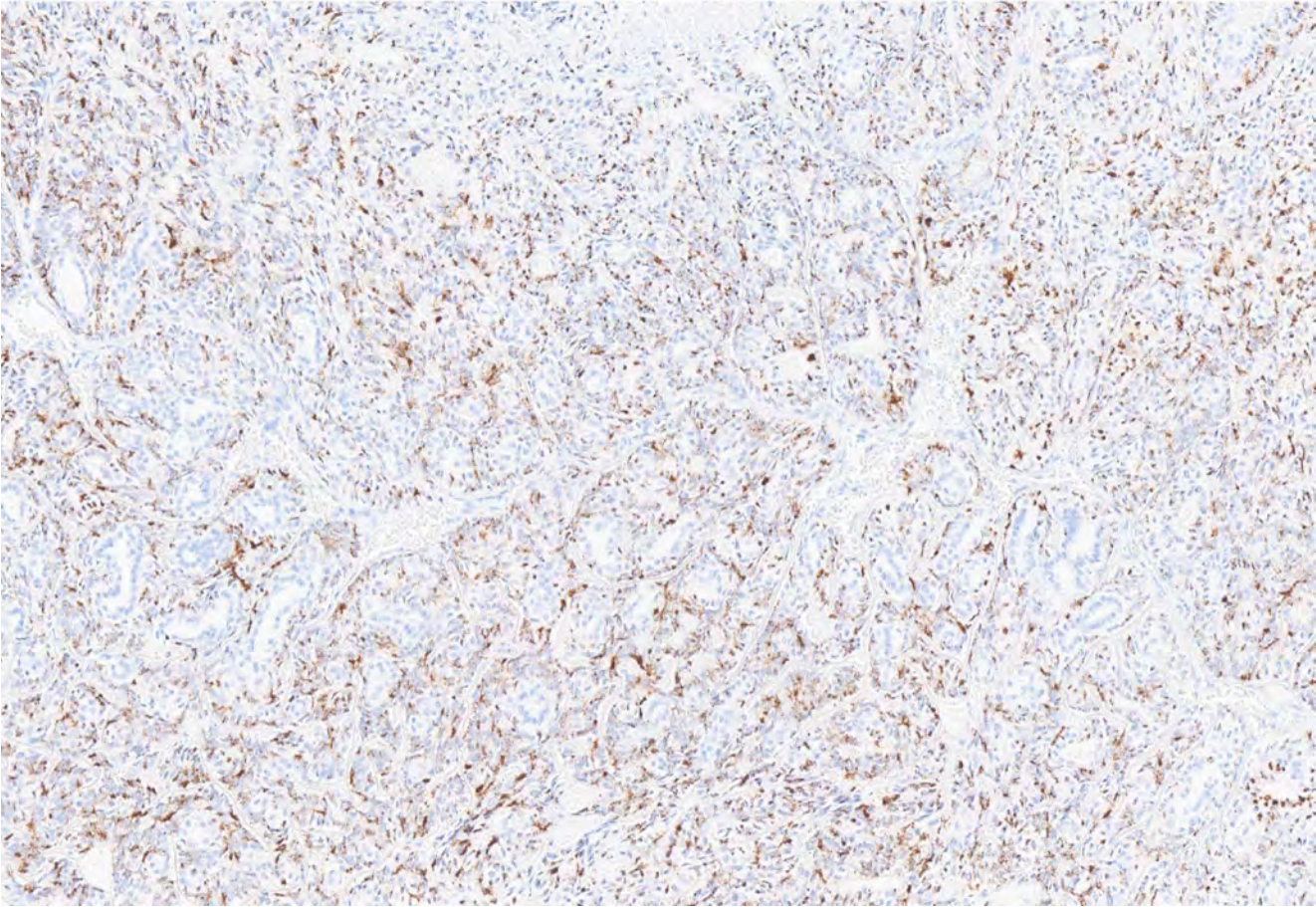
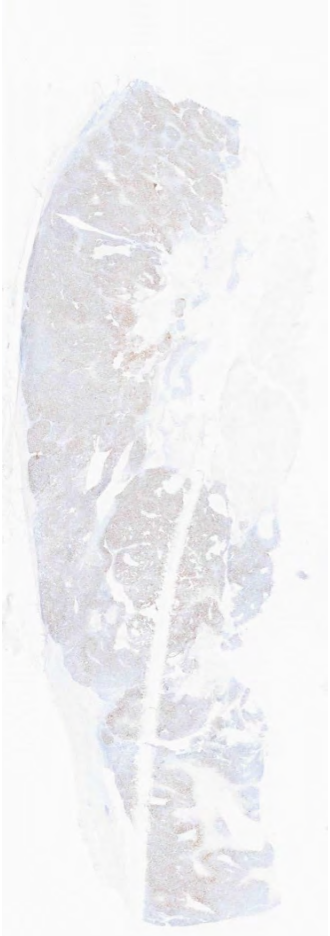IHC for Sox10



What is Your Diagnosis?

Case 2: 76 M, axillary mass

Another Test: ISH for HPV42



NGS to Detect Virus-Tumor Associations

The Journal of Molecular Diagnostics, Vol. ■, No. ■, ■ 2022



the Journal of
Molecular
Diagnostics

jmdjournal.org

Defining Novel DNA Virus-Tumor Associations and Genomic Correlates Using Prospective Clinical Tumor/Normal Matched Sequencing Data

Chad M. Vanderbilt,* Anita S. Bowman,* Sumit Middha,* Kseniya Petrova-Drus,* Yi-Wei Tang, Xin Chen, Youxiang Wang, Jason Chang,* Natasha Rekhtman,* Klaus J. Busam,* Sounak Gupta,* Meera Hameed,* Maria E. Arcila,* Marc Ladanyi,* Michael F. Berger,* Snjezana Dogan,* and Ahmet Zehir*

Chad Vanderbilt and colleagues

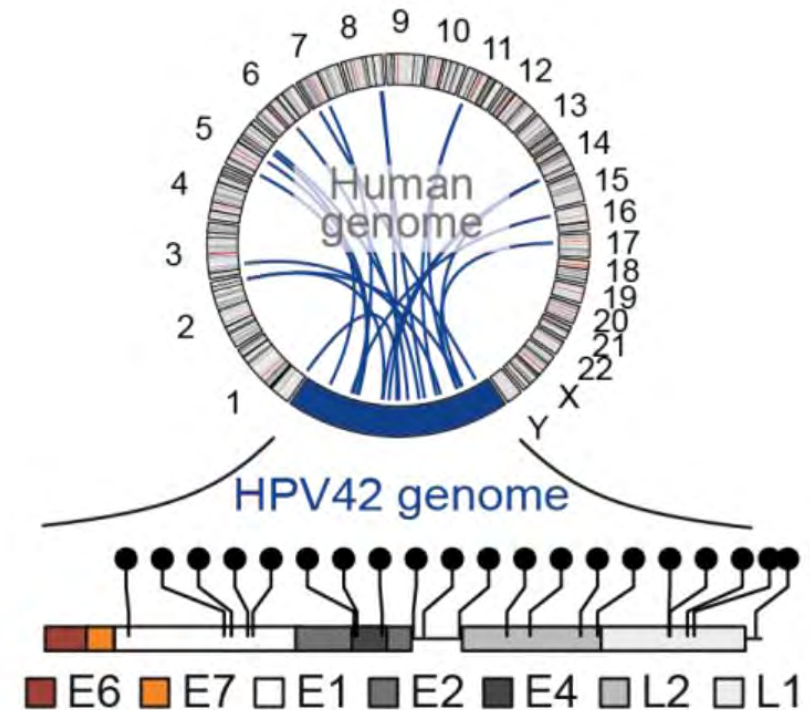
Human Papillomavirus 42 Drives Digital Papillary Adenocarcinoma and Elicits a Germ Cell-like Program Conserved in HPV-Positive Cancers

Lukas Leidencker^{1,2}, Tobias Neumann^{1,2,3}, Pauline S. Jung^{1,2,4}, Shona M. Cronin^{1,2}, Thomas L. Steinacker⁵, Alexander Schleiffner¹, Michael Schutzbier^{1,5,6}, Karl Mechtler^{1,5,6}, Thibault Kervarrec⁷, Estelle Laurent⁸, Kamel Bachiri⁹, Etienne Coyaud⁹, Rajmohan Murali⁹, Klaus J. Busam⁹, Babak Itzinger-Monshi¹⁰, Reinhard Kirnbauer⁴, Lorenzo Cerroni¹¹, Eduardo Calonje¹², Arno Rütten¹³, Frank Stubenrauch¹⁴, Klaus G. Griewank¹⁵, Thomas Wiesner^{4,16}, and Anna C. Obenaus¹

Anna Obenaus, Thomas Wiesner and colleagues

Sequence Analysis Detects HPV42 in DPAC

- 55,000 cases analyzed by MSK-IMPAC
- 4 skin tumors positive for HPV42
- All had been diagnosed as DPAC



DPAC – Positive for HPV42

Acral Sites

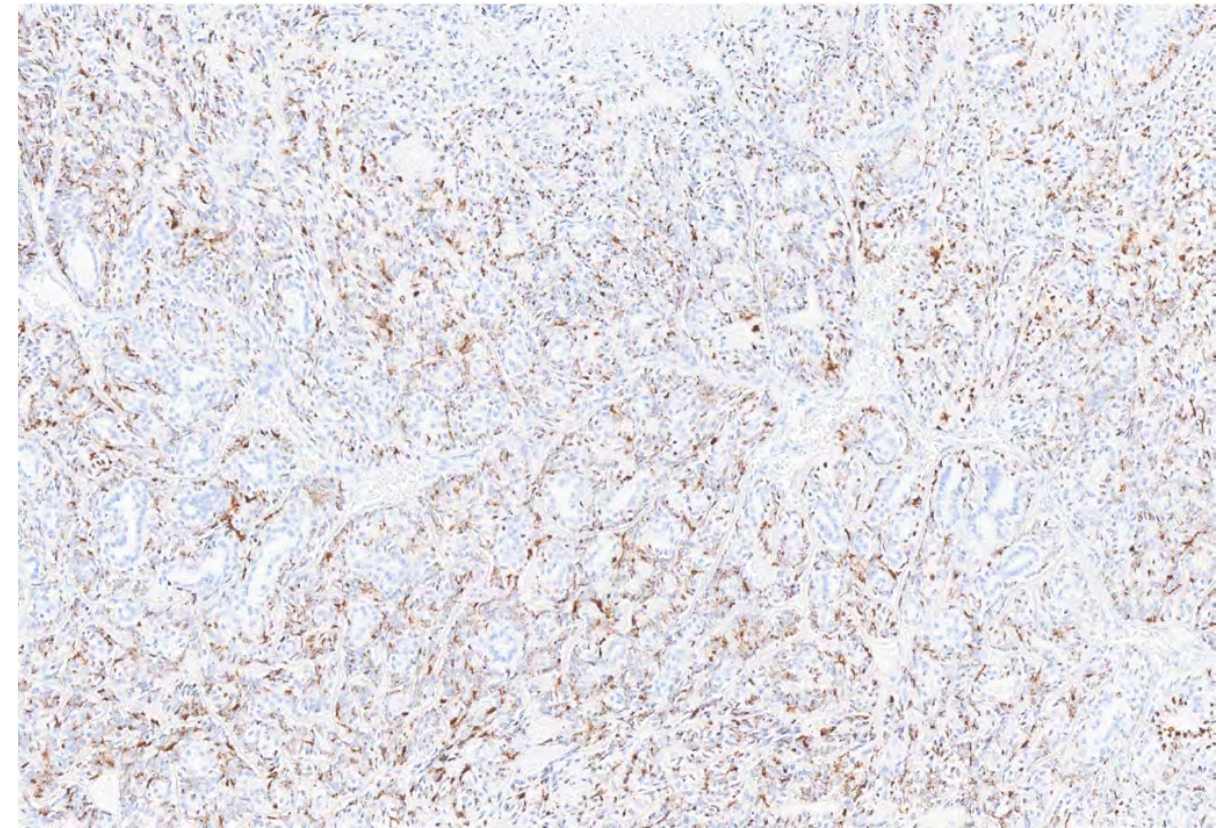
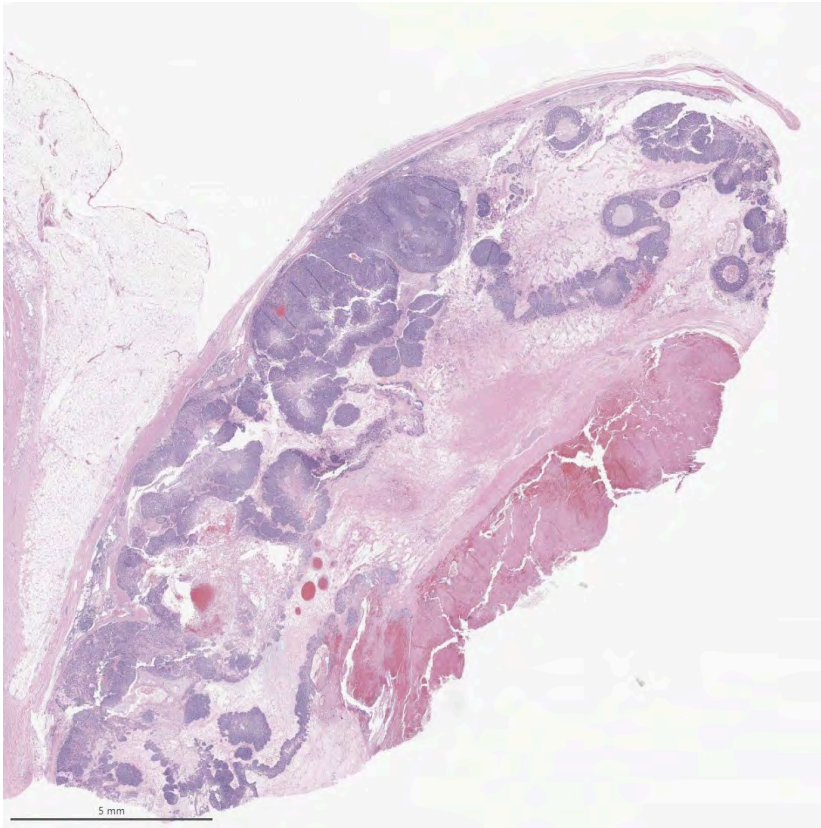
Case	Age (yrs)	Gender	Anatomic Site	Size (mm)	Growth	ISH HPV42	Metastasis
1	68	M	rt 3rd finger	17	nodular	POSITIVE	
2	36	M	rt 2nd finger	8	nodular	POSITIVE	LN, ST
3	60	M	rt 2nd finger	30	infiltrative	POSITIVE	
4	68	M	rt 3rd finger	5	nodular	POSITIVE	
5	31	M	rt 4 th toe	13	nodular	POSITIVE	LN (4/10)
6	21	M	rt great toe	20	nodular	POSITIVE	
7	37	M	rt 5 th finger	18	nodular	POSITIVE	
8	65	M	lt thumb	16	nodular	POSITIVE	LN

Non-Acral Sites

9	80	M	scrotum	20	nodular	POSITIVE	
10	77	M	scrotum	8	nodular	POSITIVE	

Mod Pathol. 2022 Oct;35(10):1405-1410.

Case 2 – Digital Papillary Adenocarcinoma



Clinical History

- Prior diagnosis of "benign" eccrine tumor in 2008; narrowly excised
- Recurred in 2010; excised with negative margin

Final Anatomic Diagnosis

1. THUMB, SOFT TISSUE, LEFT

Eccrine Acrospiroma (Eccrine Nodular Hidradenoma)

FROZEN SECTION DIAGNOSIS: Epithelial lesion. Wait for permanent section for further classification

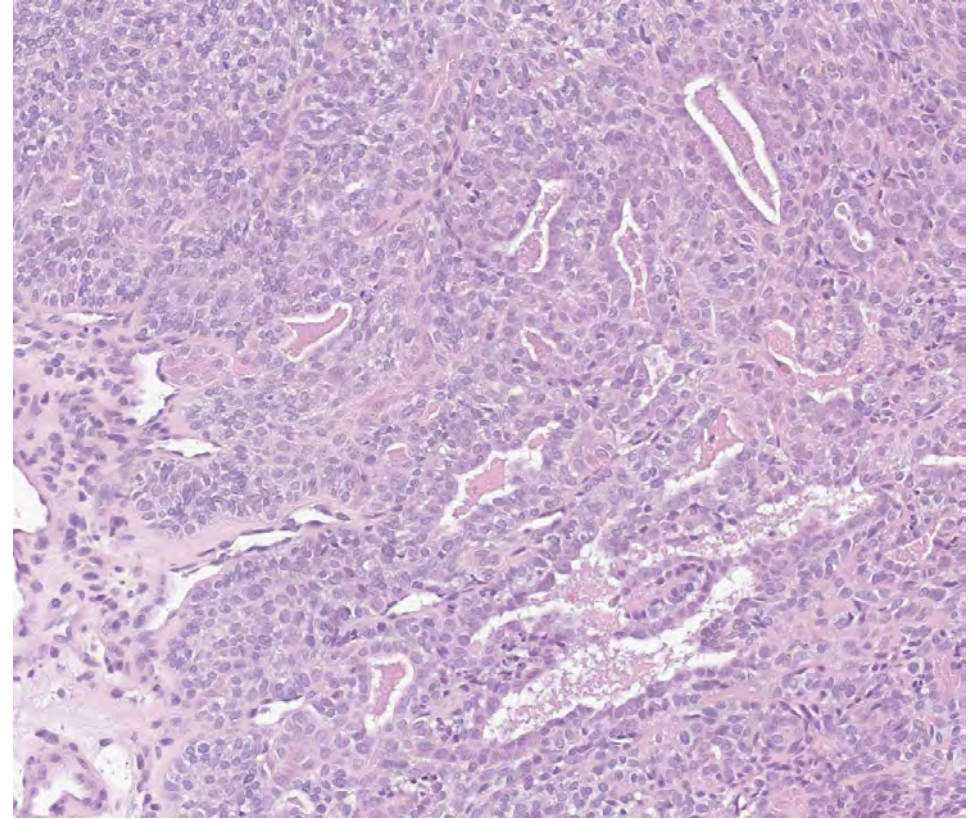
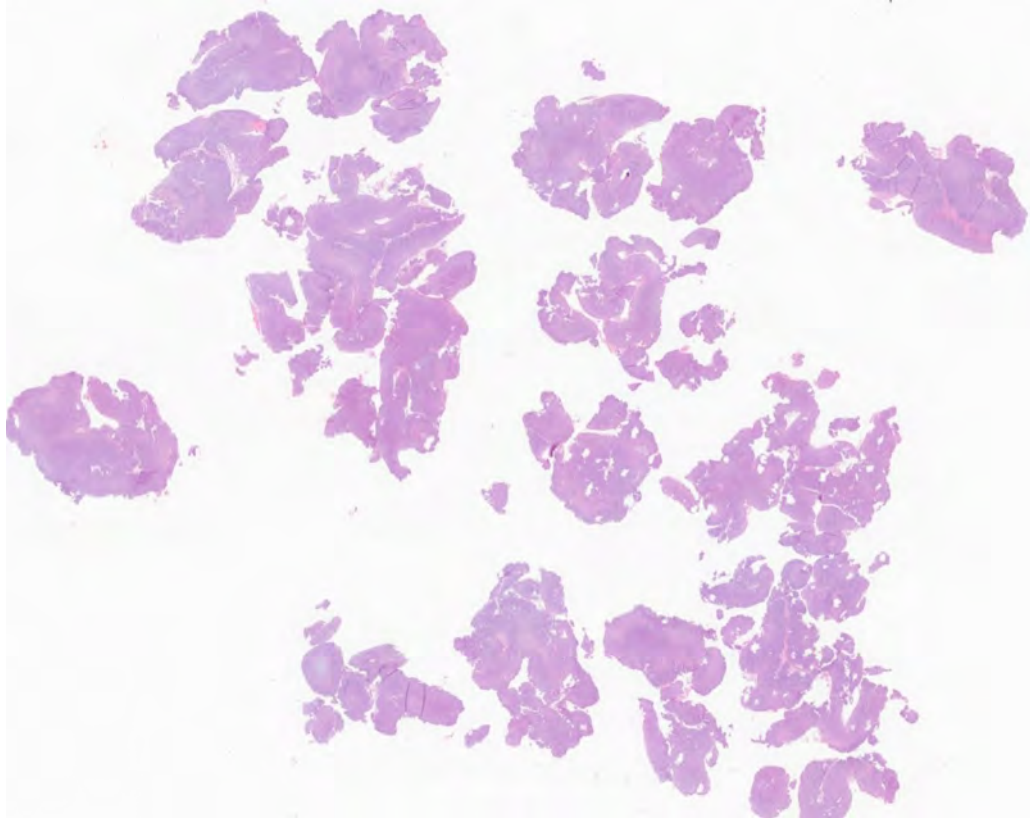
2. THUMB, SOFT TISSUE, LEFT

Eccrine Acrospiroma (Eccrine Nodular Hidradenoma)

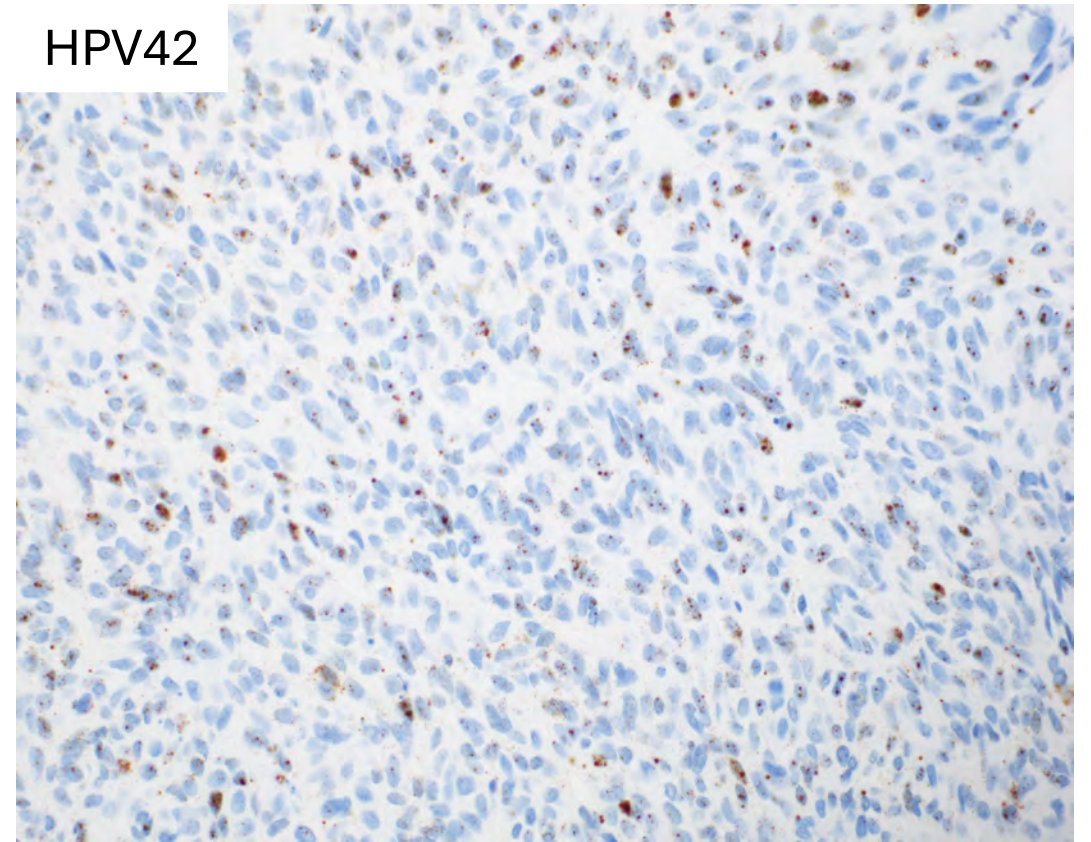
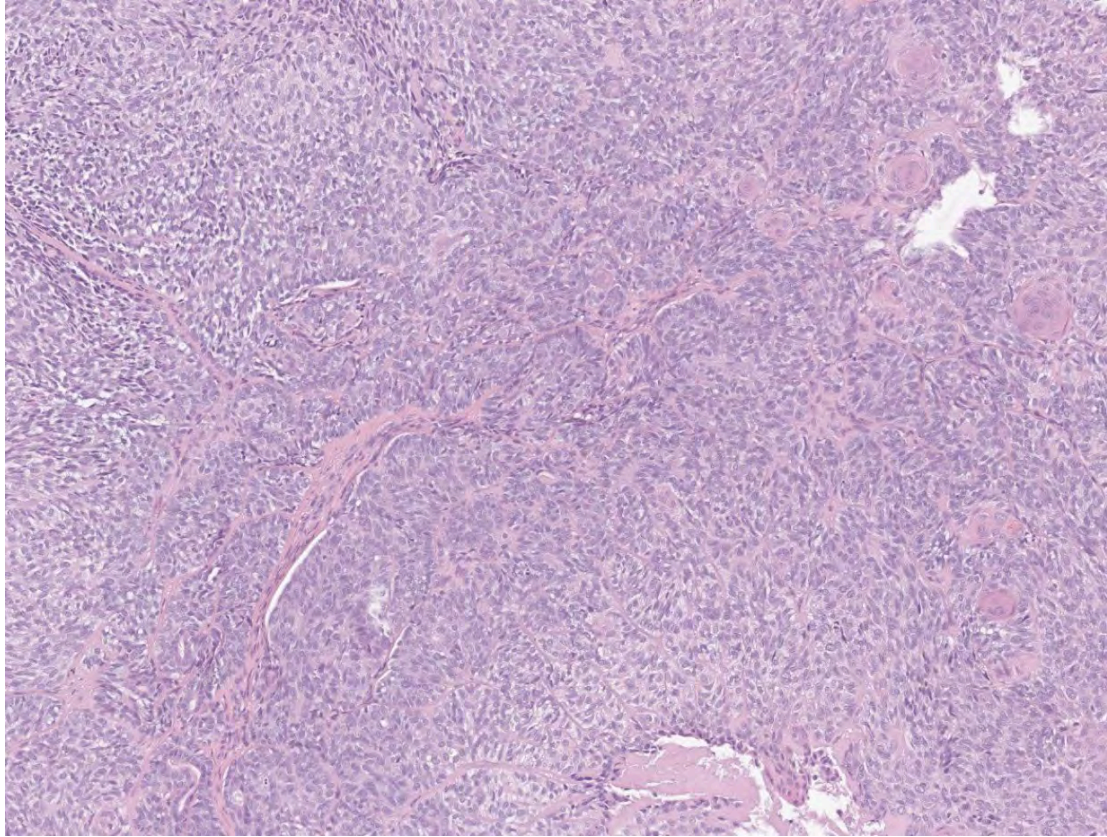
Comment on Case

Although eccrine acrospiromas are benign tumors which do not exhibit a high rate of recurrence, close clinical follow-up is recommended due to the marginal excision of the tumor and the lack of clear margins of resection.

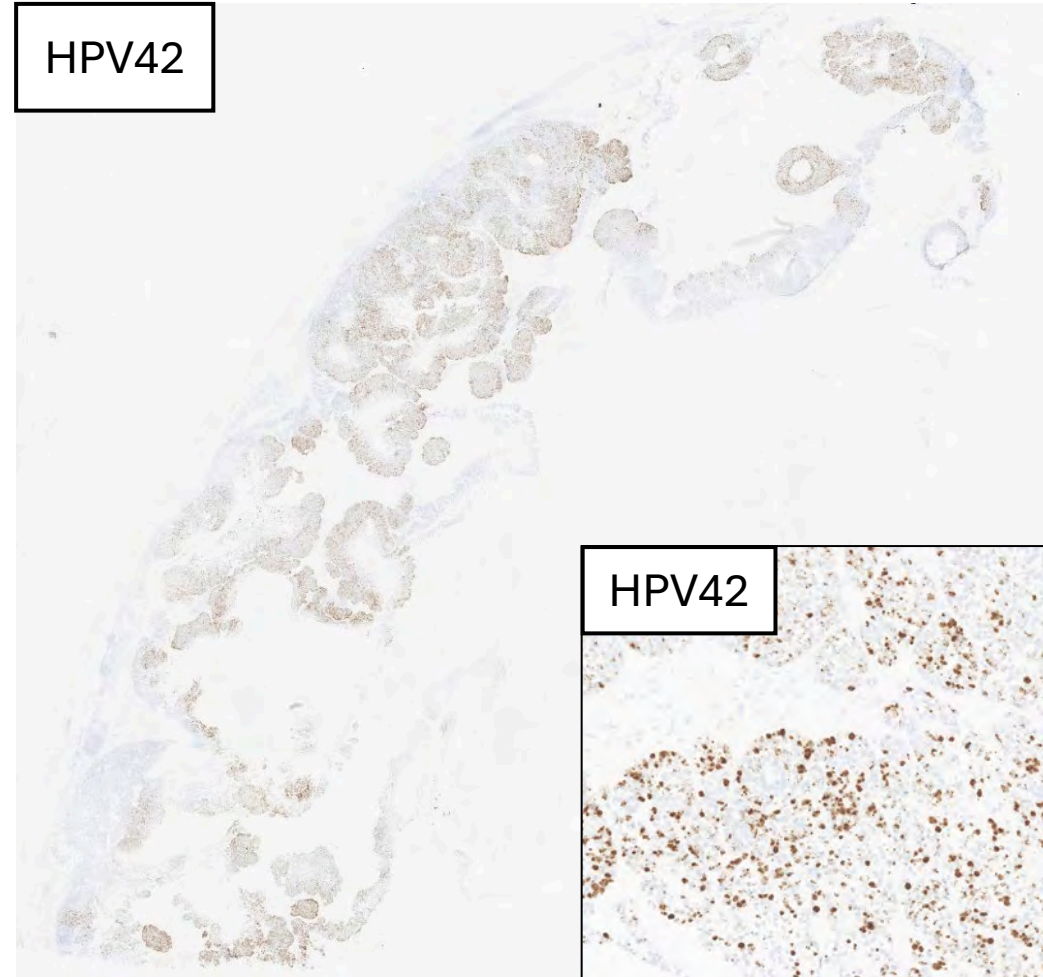
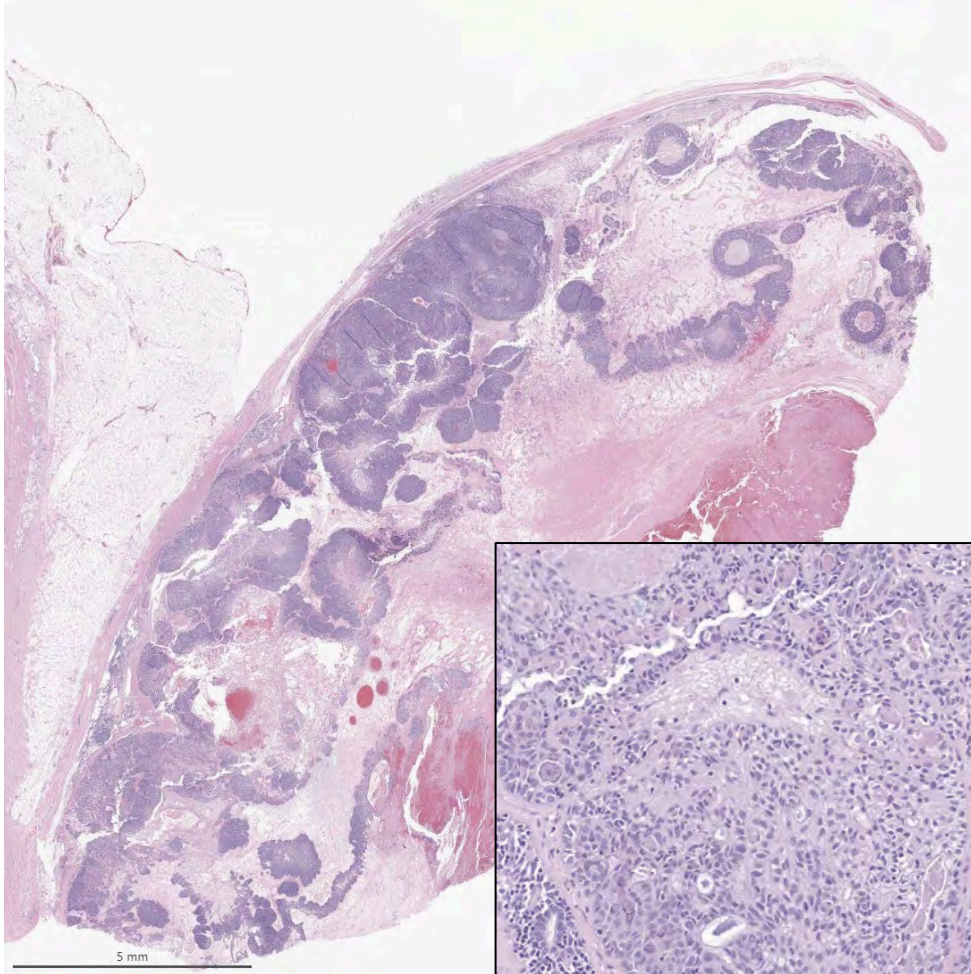
Biopsy from 2008

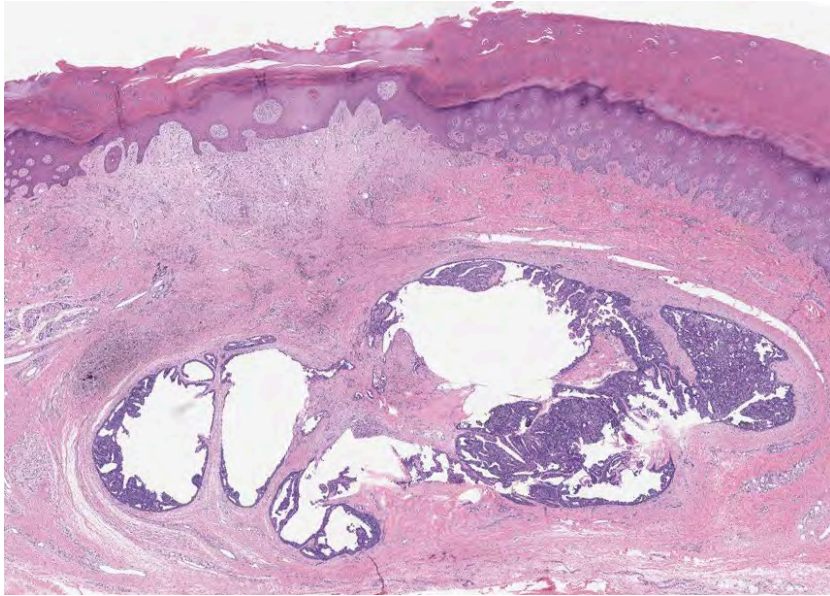


DPAC – Positive for HPV42



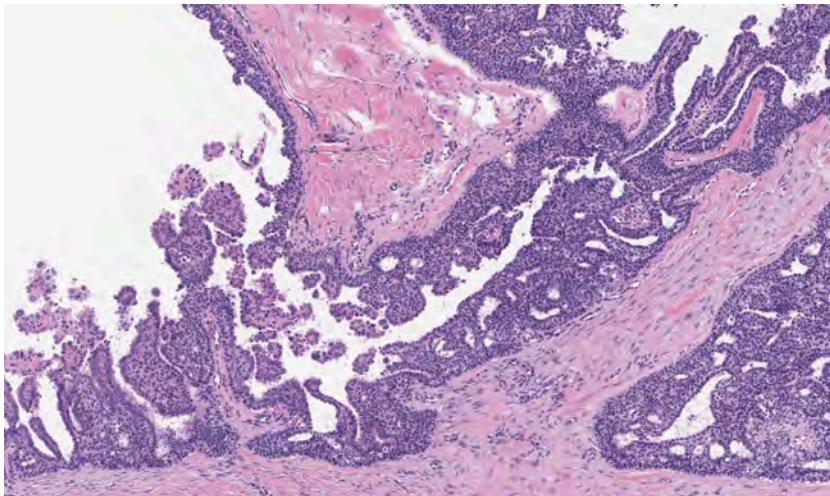
Case 2 - Diagnosis: Metastatic DPAC





Digital Papillary Adenocarcinoma (DPAC)

- Incidence: 0.08 per 1,000,000
- Median age at diagnosis: 50
- Men: Women = 4:1
- Predilection for digits and toes
- Risk for metastasis: approx. 15%
- Treatment: Surgical resection



DPAC – A Diagnostic Challenge

ORIGINAL ARTICLE

“Apocrine Hidrocystoma and Cystadenoma”-like Tumor of the Digits or Toes

A Potential Diagnostic Pitfall of Digital Papillary Adenocarcinoma

Ana-Maria Molina-Ruiz, MD, Mar Llamas-Velasco, MD,† Arno Rütten, MD,‡
Lorenzo Cerroni, MD,§ and Luis Requena, MD**

**Can be confused with a
benign sweat gland tumor**

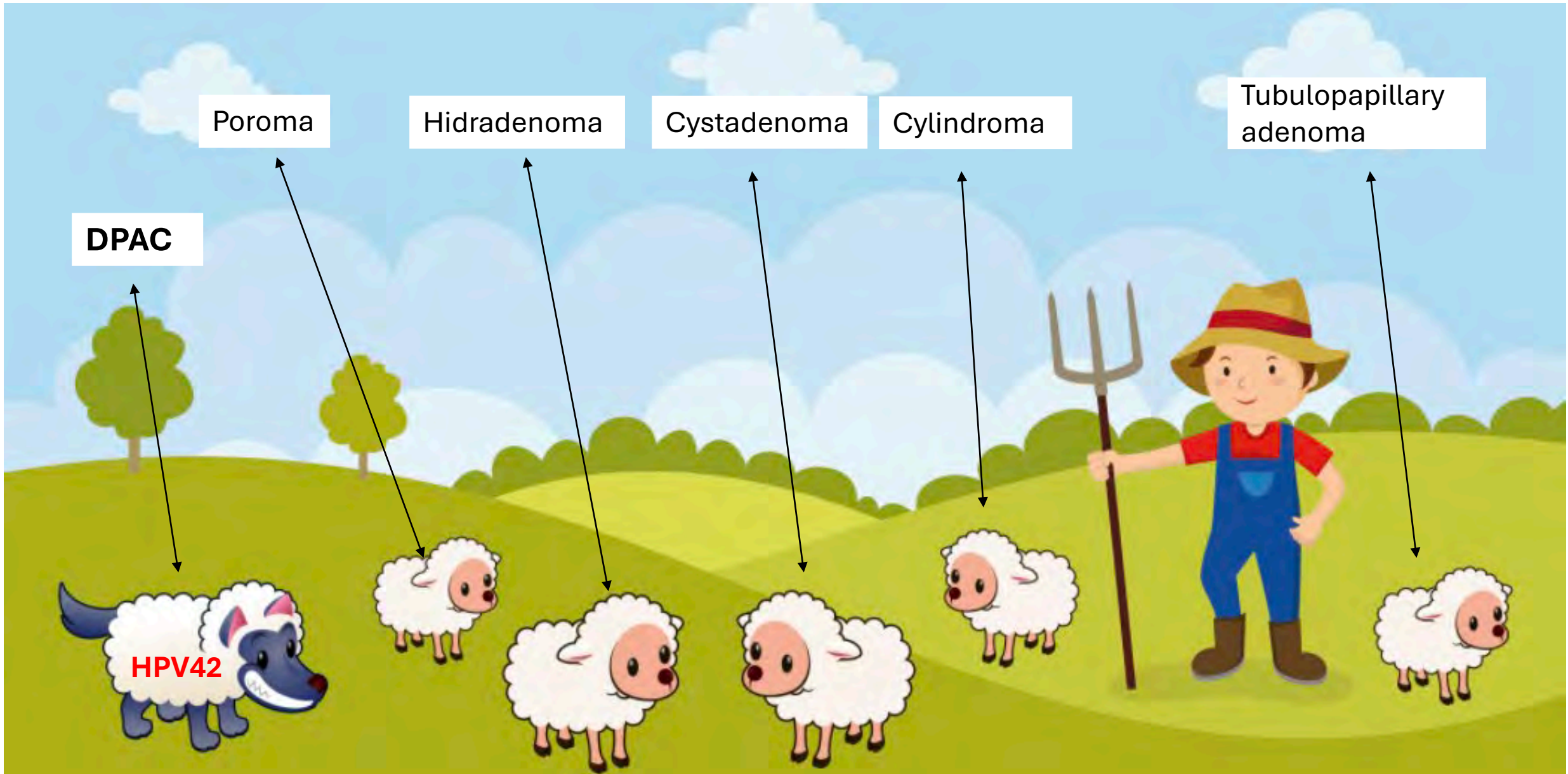
ORIGINAL ARTICLE

Clinicopathologic Characterization of Hidradenoma on Acral Sites

A Diagnostic Pitfall With Digital Papillary Adenocarcinoma

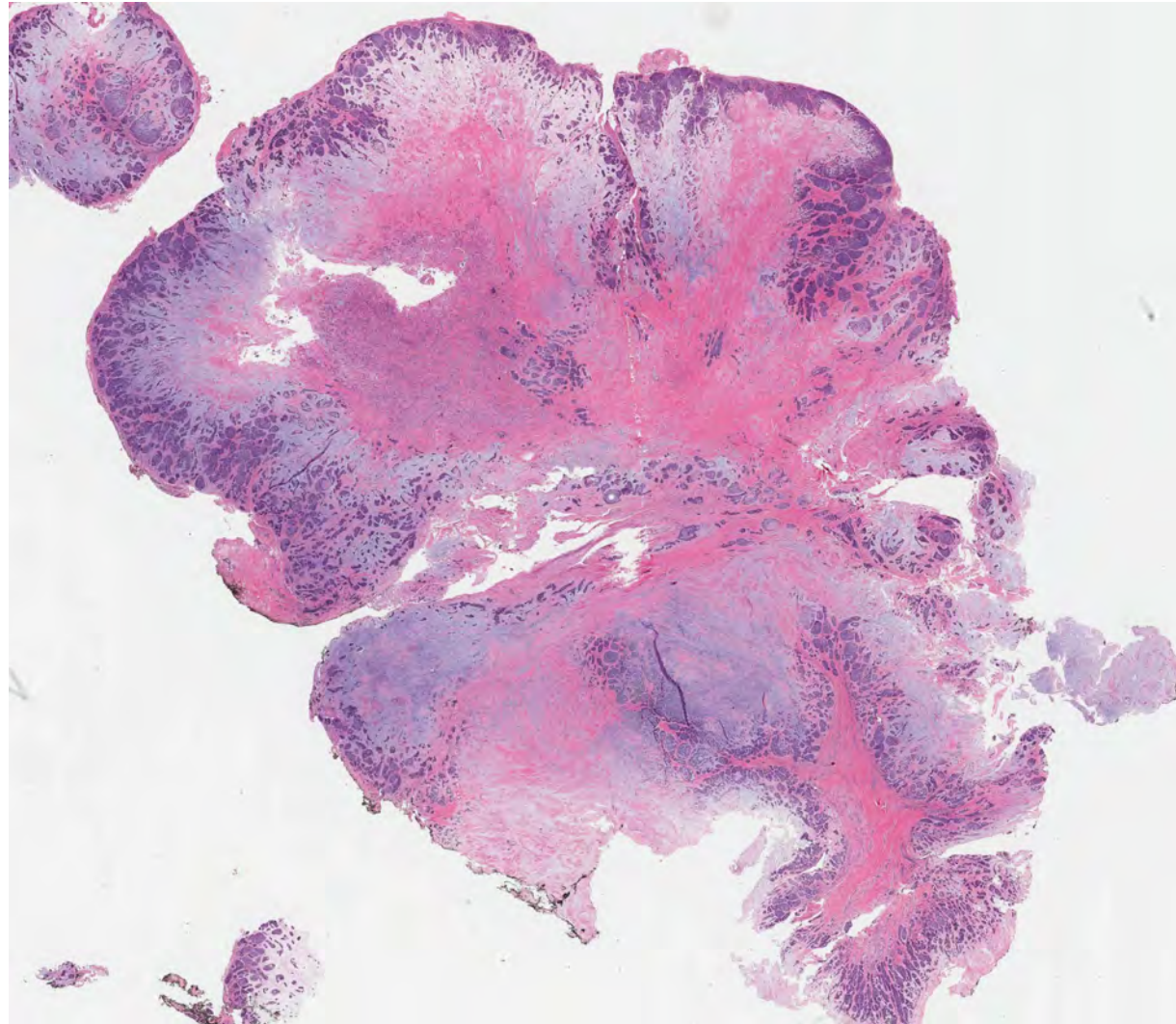
Katharina Wiedemeyer, MD,† Pavandeep Gill, MD,* Michelle Schneider, MD,*
Peter Kind, MD,‡ and Thomas Brenn, MD, PhD, FRCPath*§||*

ISH for HPV 42 for the diagnosis of DPAC



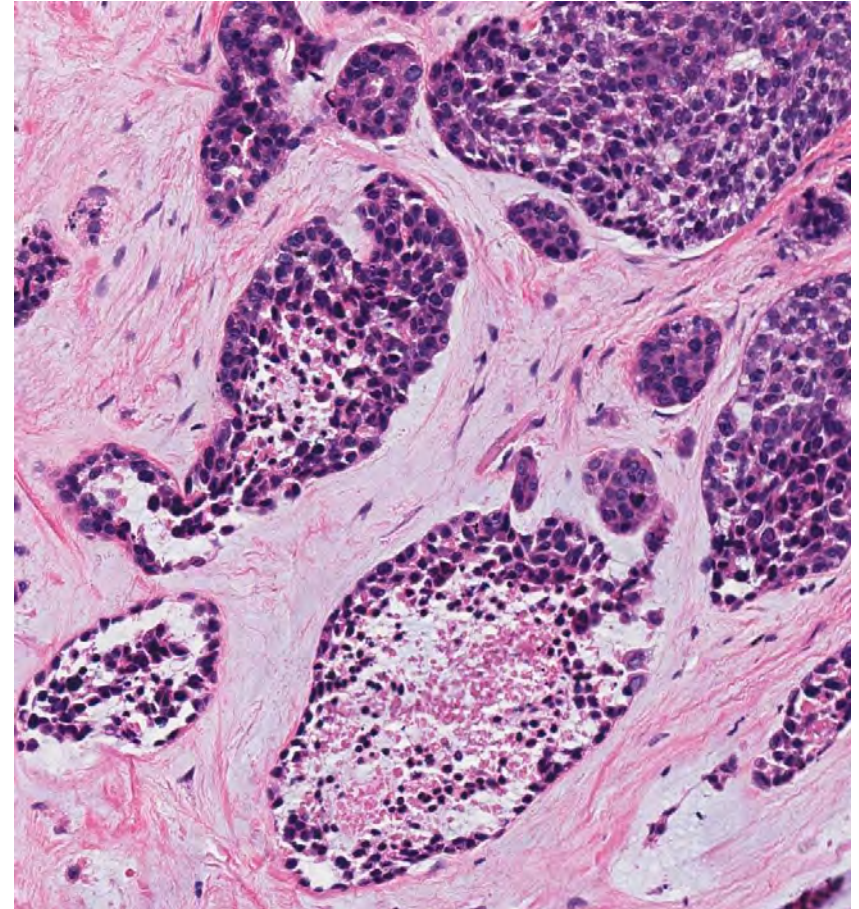
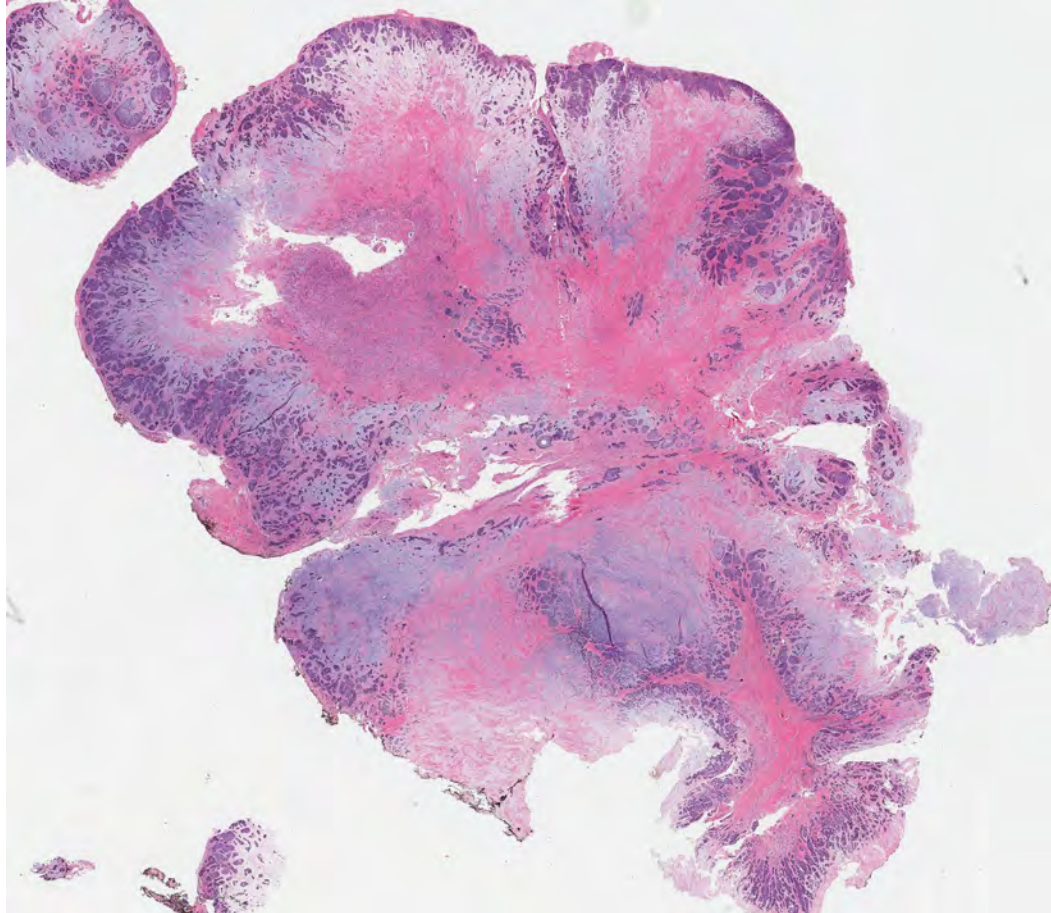
Case 3: What is Your Diagnosis?

60M,
rt index finger

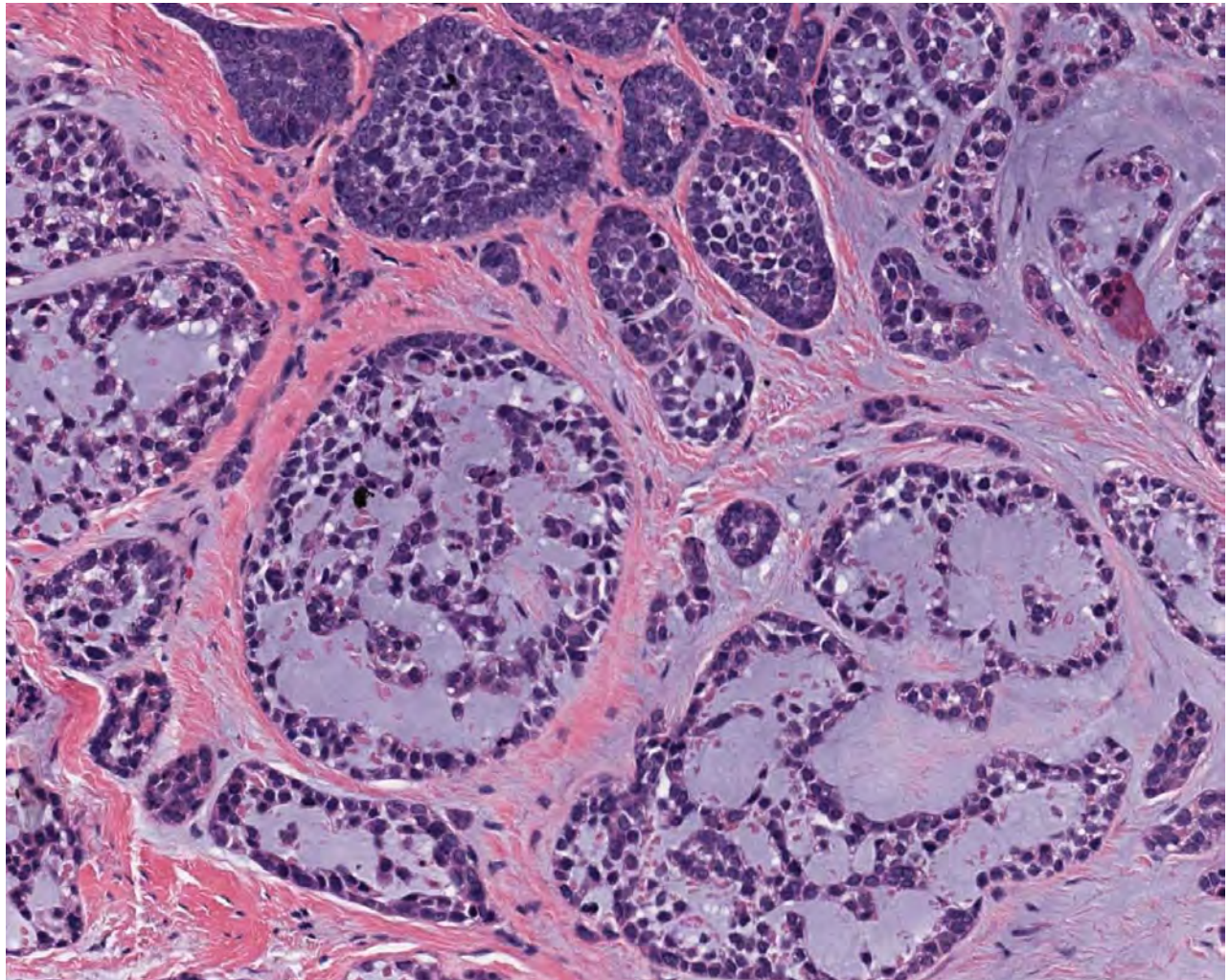
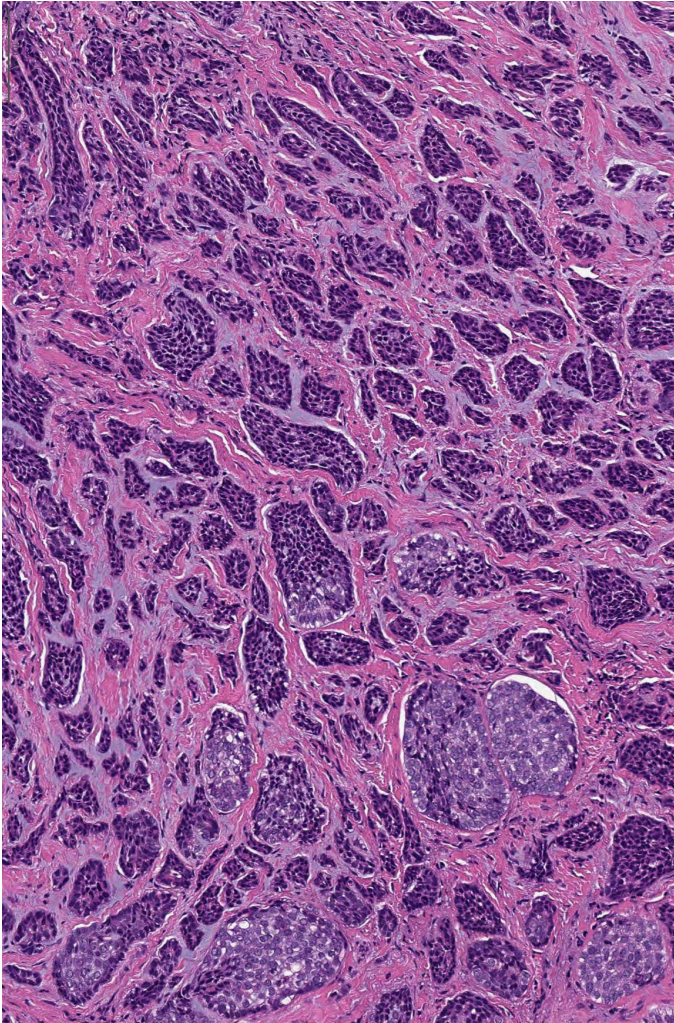


Case 3: What is Your Diagnosis?

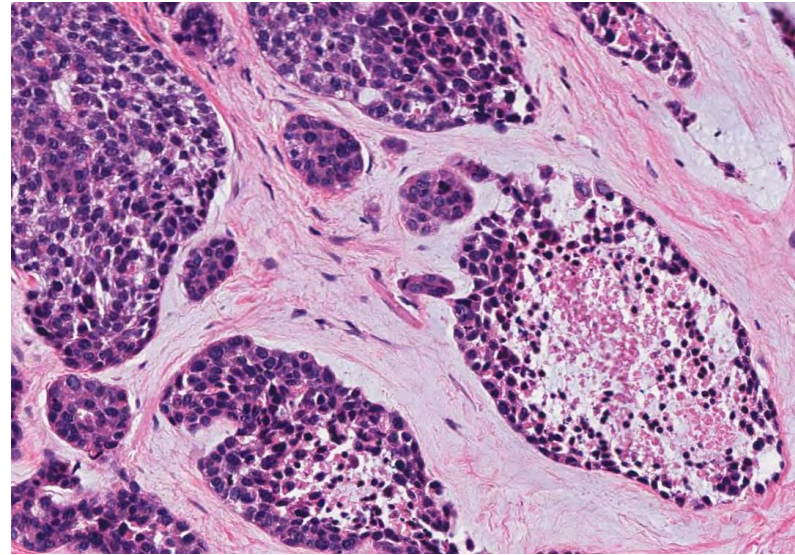
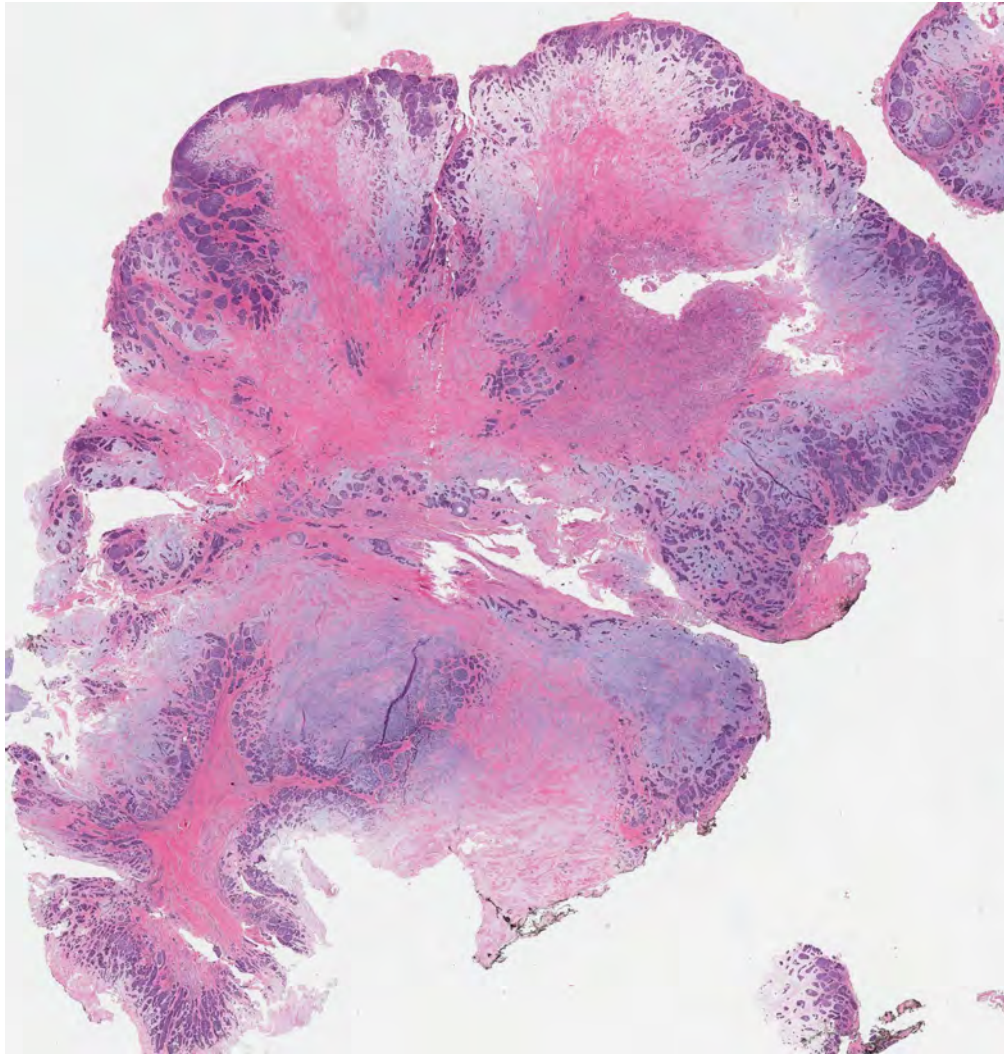
60M, rt index finger



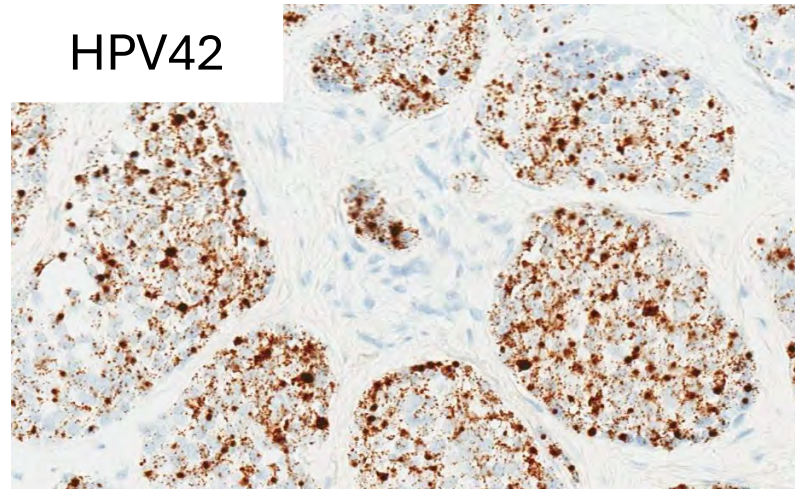
Case 3: 60 M with mass on rt index finger



Case 3: Digital Papillary Adenocarcinoma

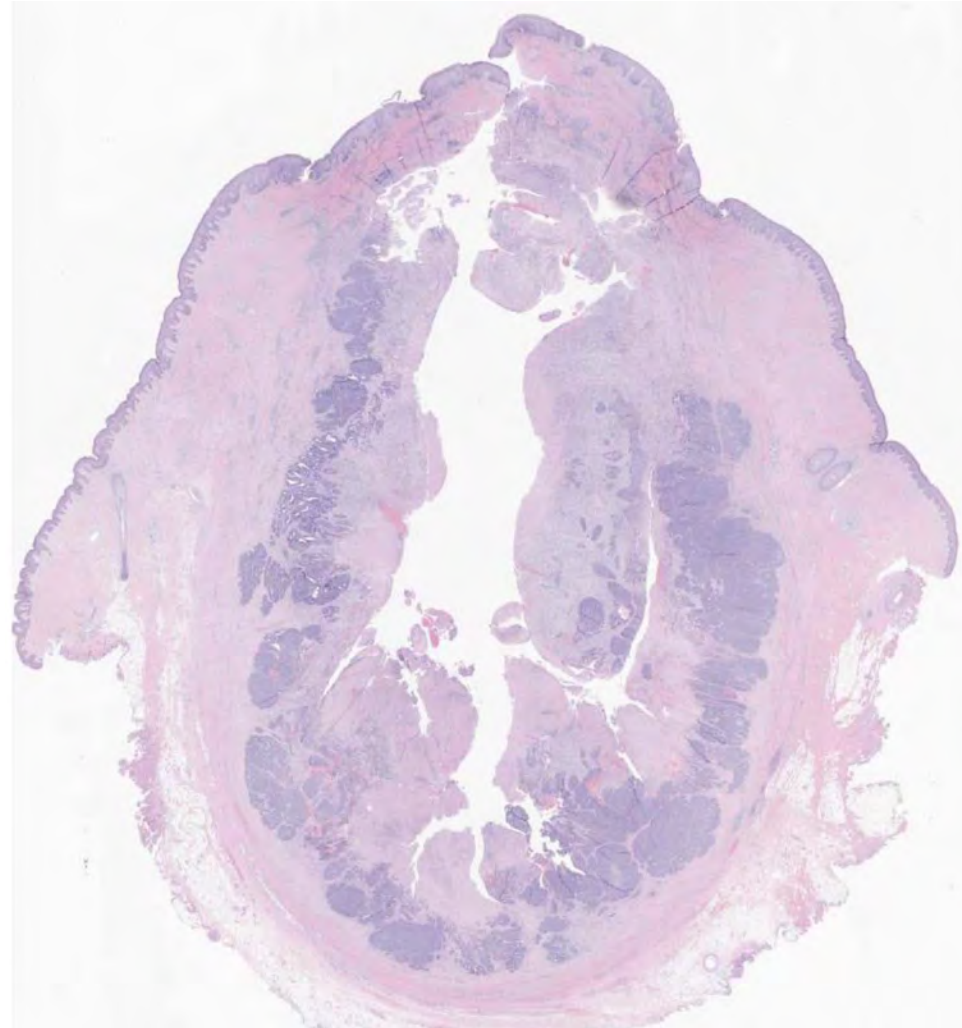


HPV42

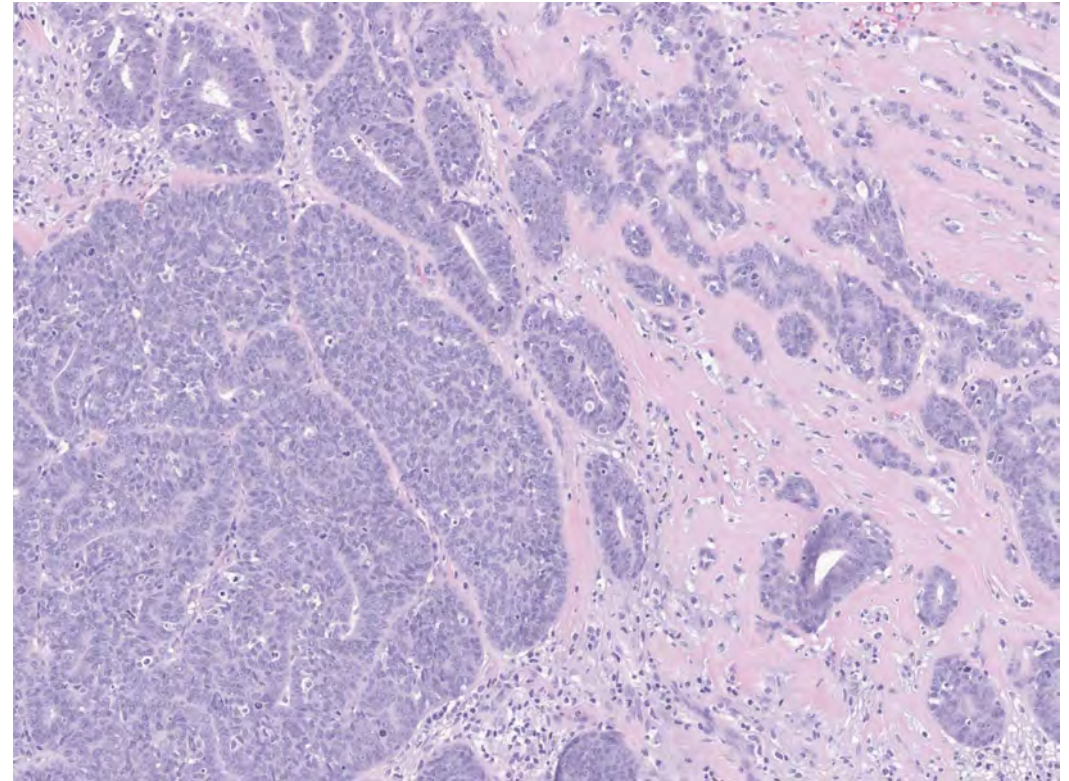
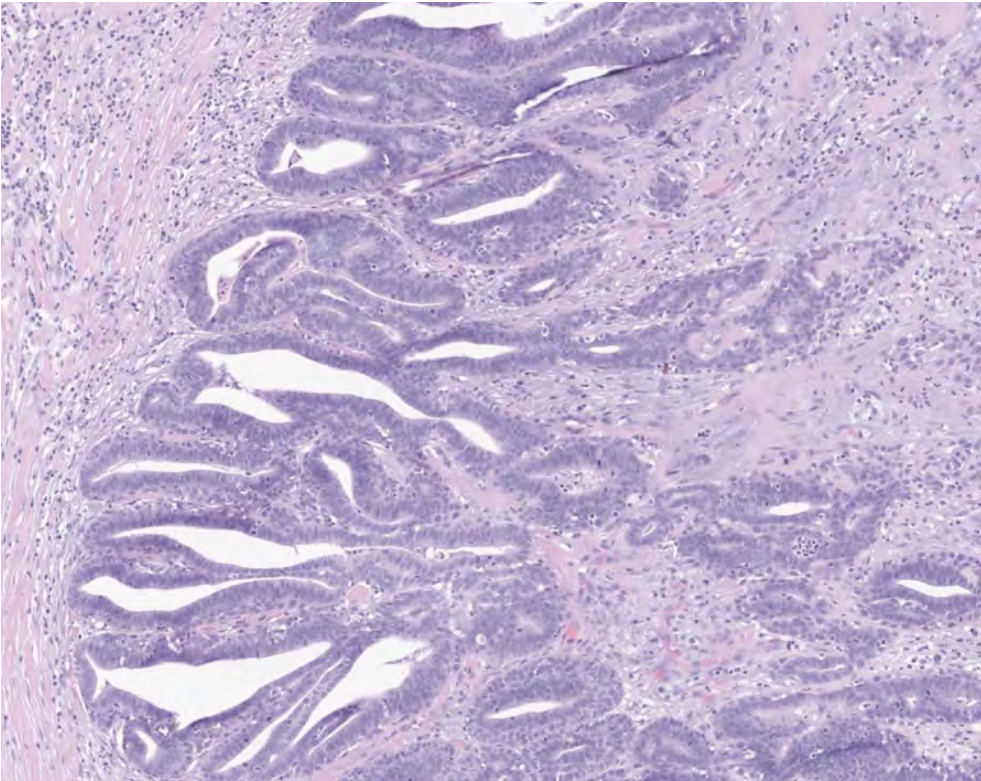


Case 4 : What is Your Diagnosis?

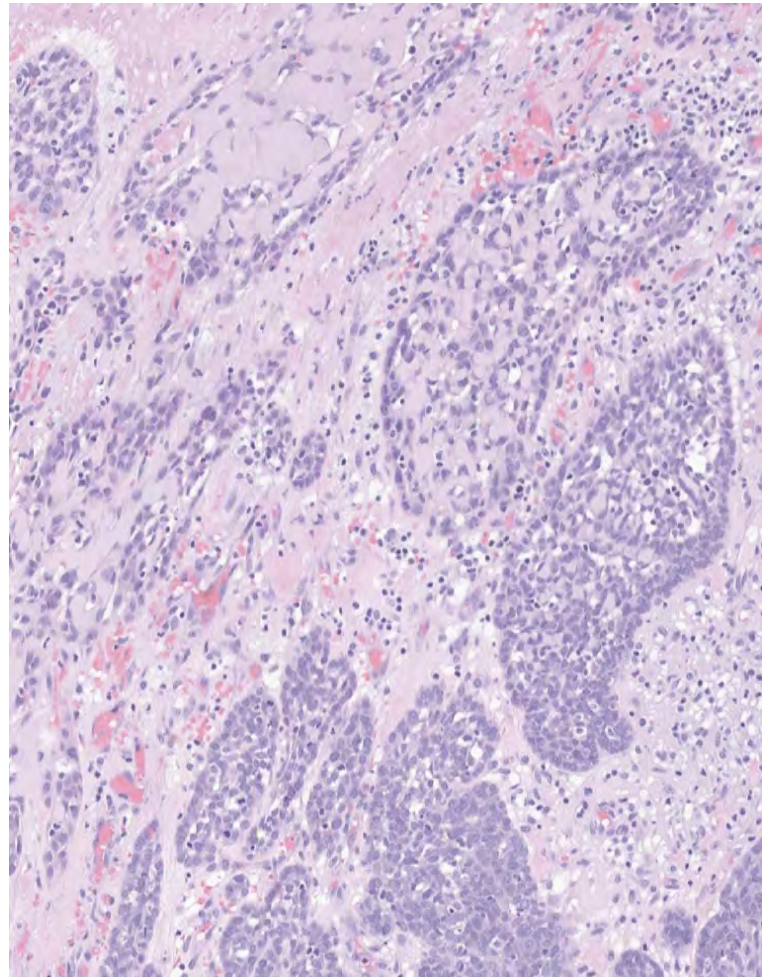
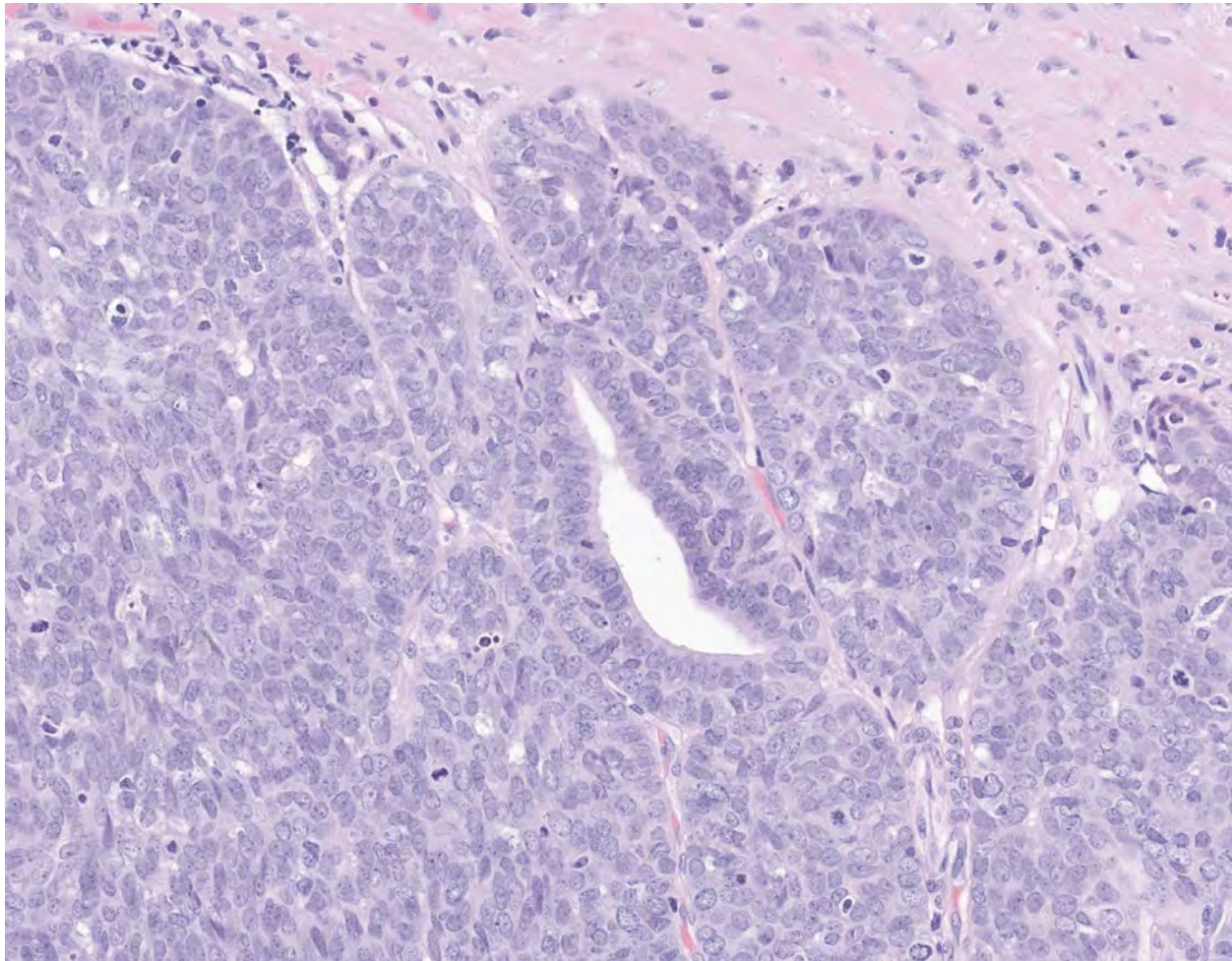
- 45F
- Vulva



What is Your Diagnosis?

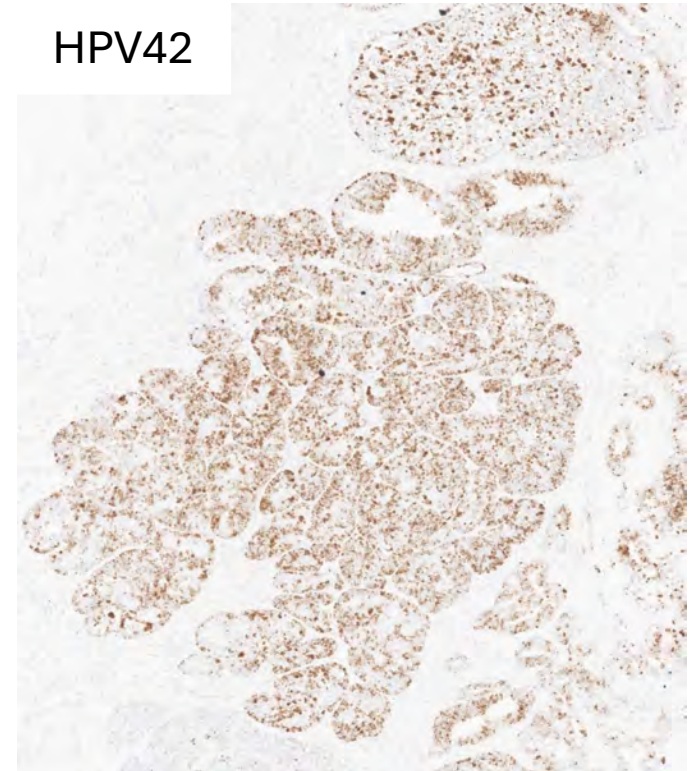
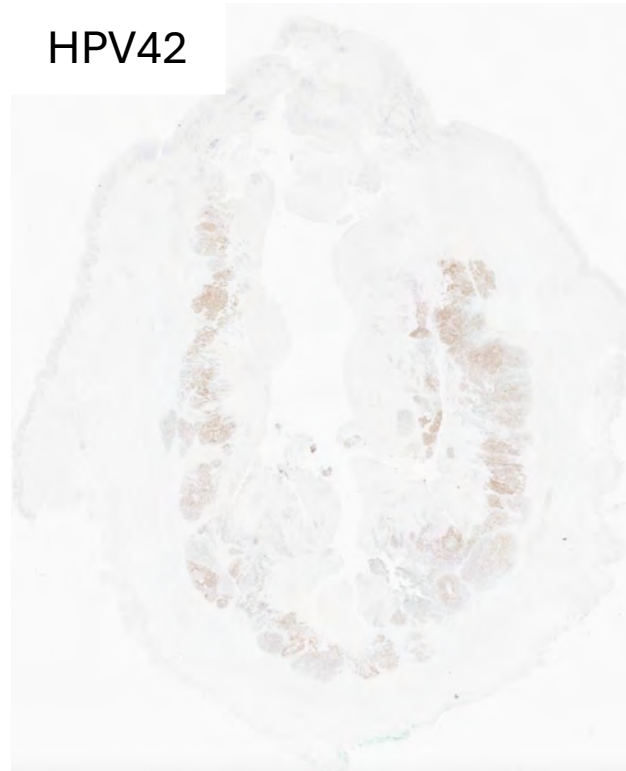
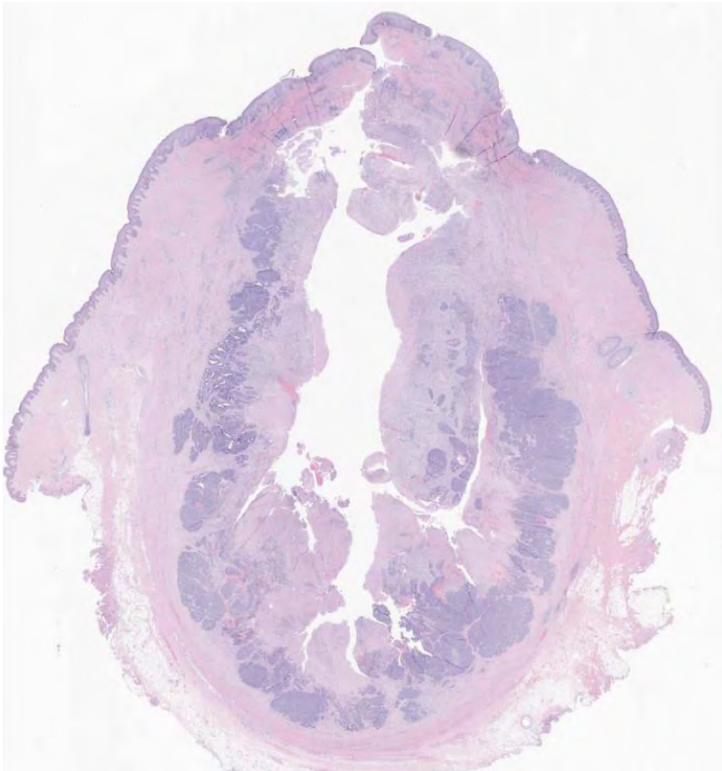


What is Your Diagnosis?



HPV42-Associated Adenocarcinoma

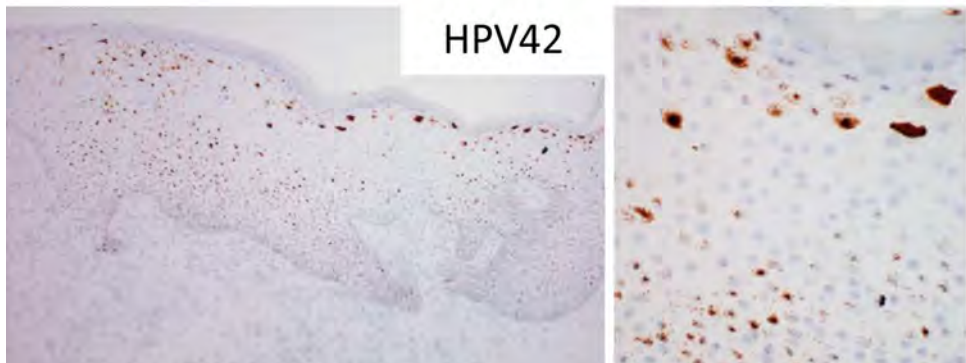
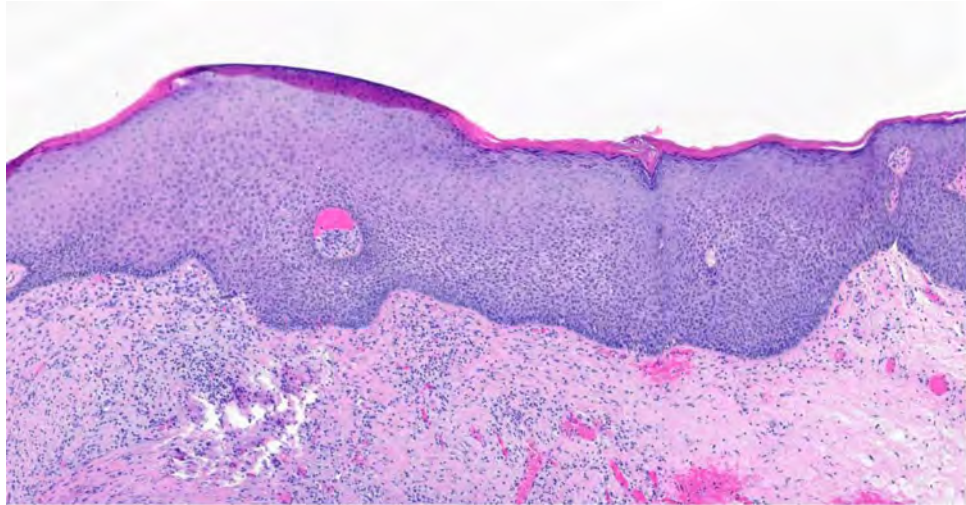
Vulvar analog to digital papillary adenocarcinoma



Lessons from cases 2- 4

- DPAC is associated with HPV 42
- DPAC is an epithelial-myoepithelial carcinoma
- ISH for HPV42 can be diagnostically helpful
 - Recognition of poorly differentiated DPAC
 - Distinction of DPAC from adenomas
 - Diagnosis of DPAC at non-acral sites

HPV42-associated SK-like lesion



Seborrheic Keratosis-like Lesions of the Cervix and Vagina *Report of a New Entity Possibly Related to Low-risk Human Papillomavirus Infection*

Karen L. Talia, FRCPA, MBBS and W. Glenn McCluggage, FRCPath†*

Am J Surg Pathol 2017; 41:517-24

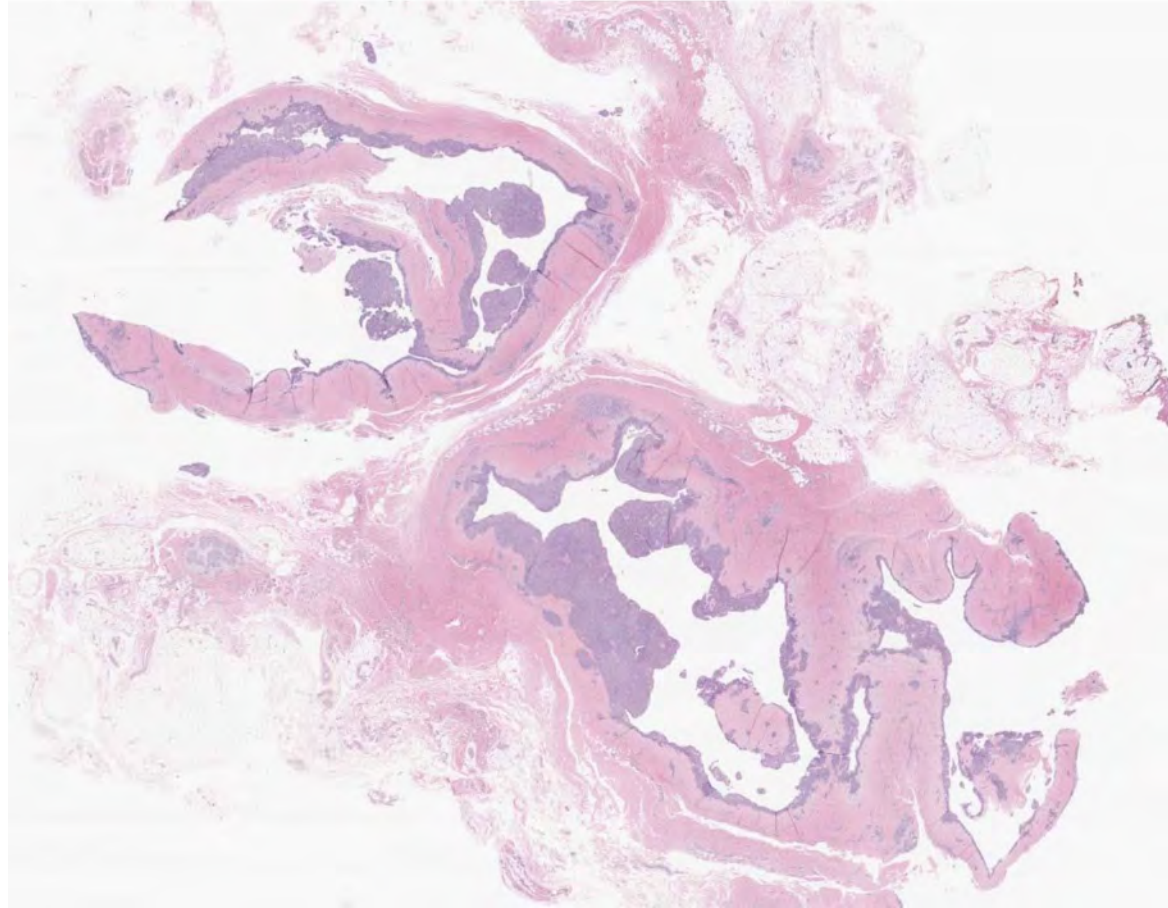
International Journal of Gynecological Pathology
41:549-654, Lippincott Williams & Wilkins, Baltimore
Copyright © 2021 by the International Society of Gynecological Pathologists

Case Report

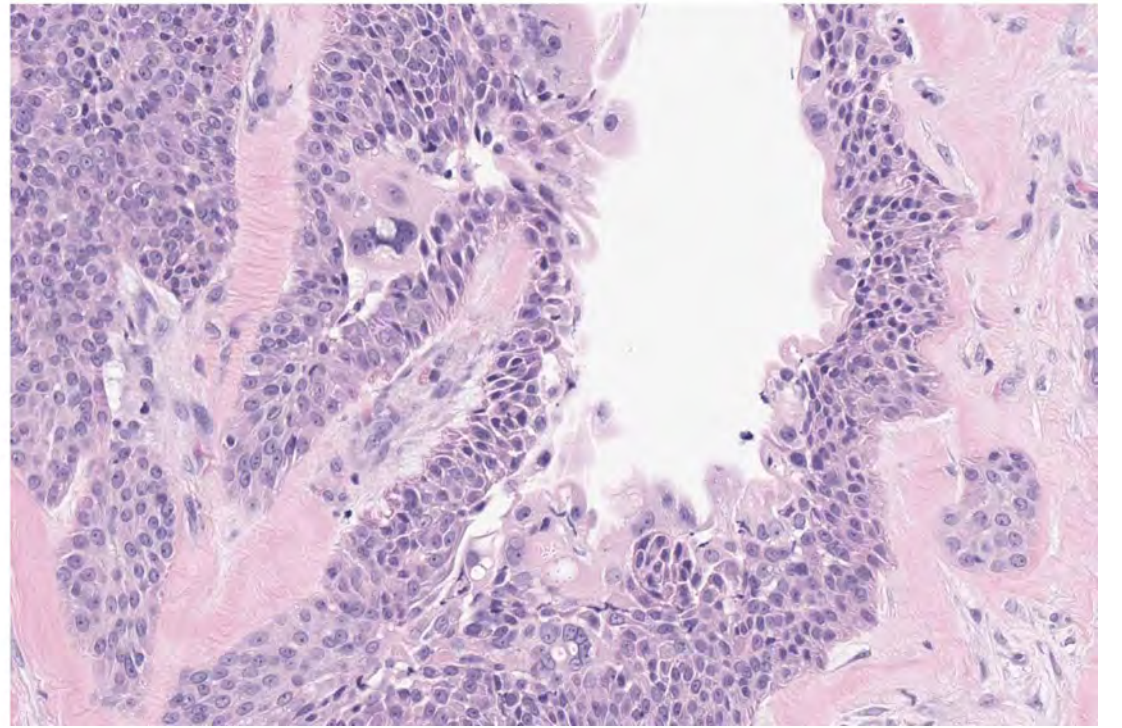
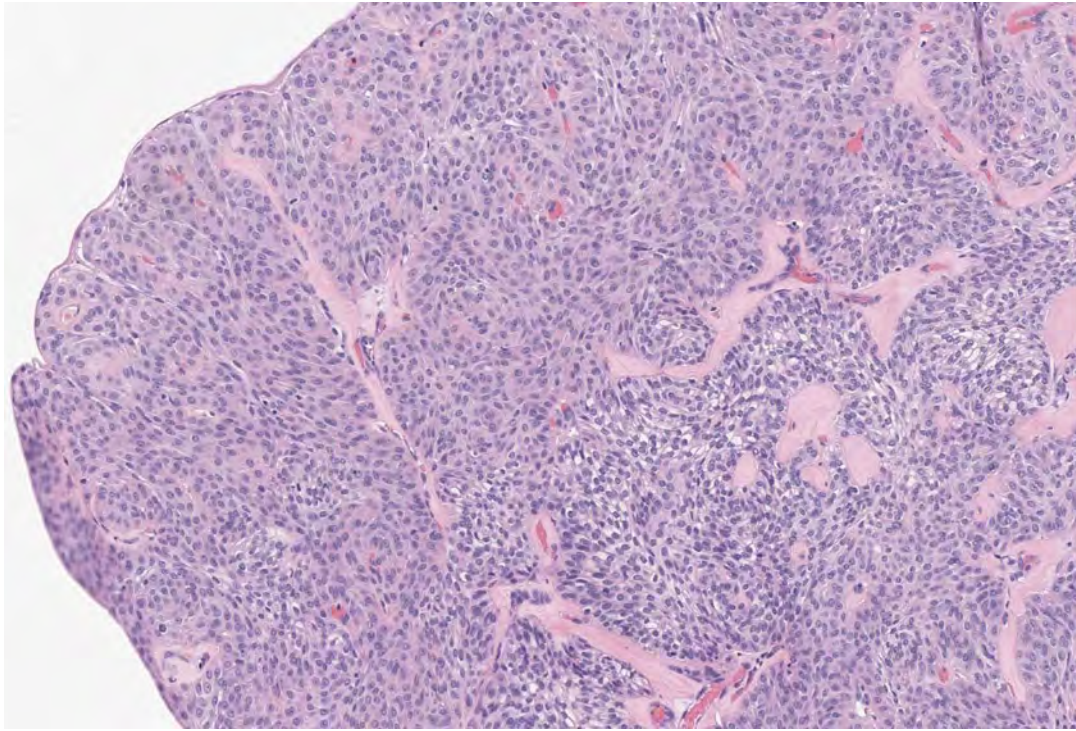
HPV42-associated Seborrheic Keratosis-like Lesion of the Cervix: First Reported Case With High-grade Morphology

*Karen L. Talia, F.R.C.P.A., Siavash Rahimi, F.R.C.Path., David Hawkes, Ph.D.,
and W. Glenn McCluggage, F.R.C.Path.*

Case 5: 72 M, right hand

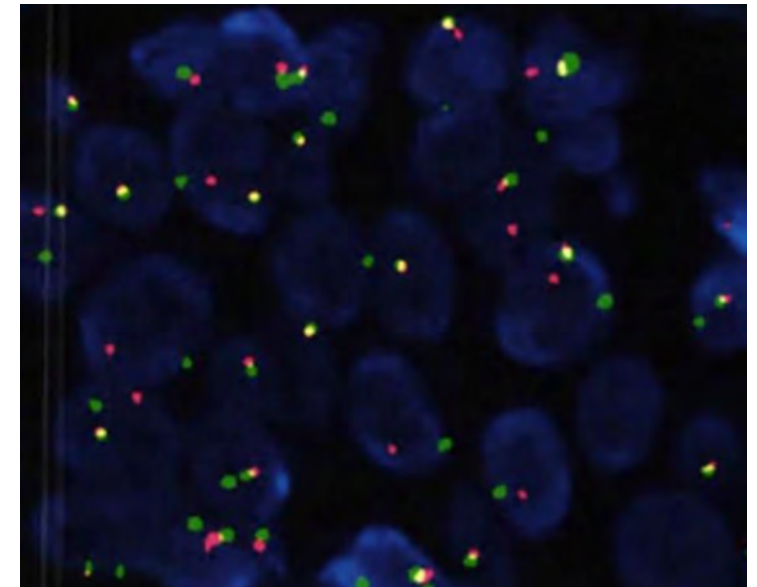
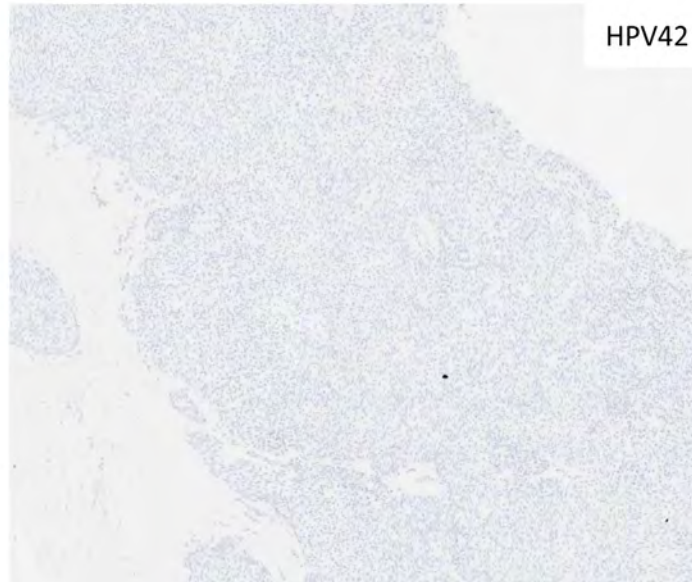
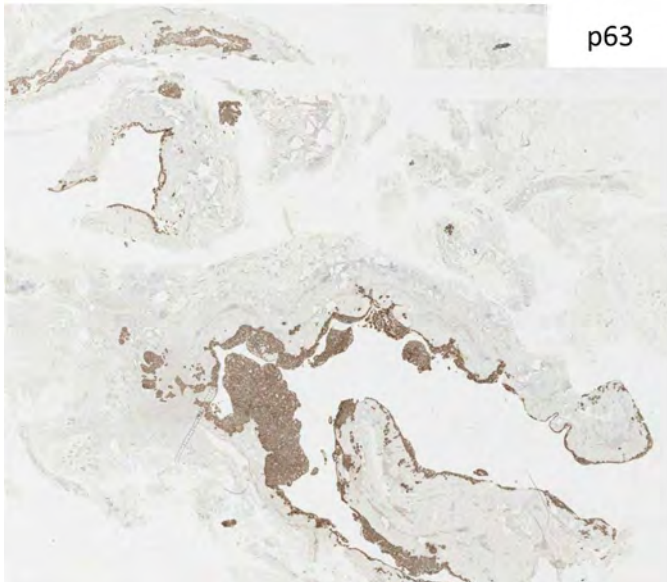
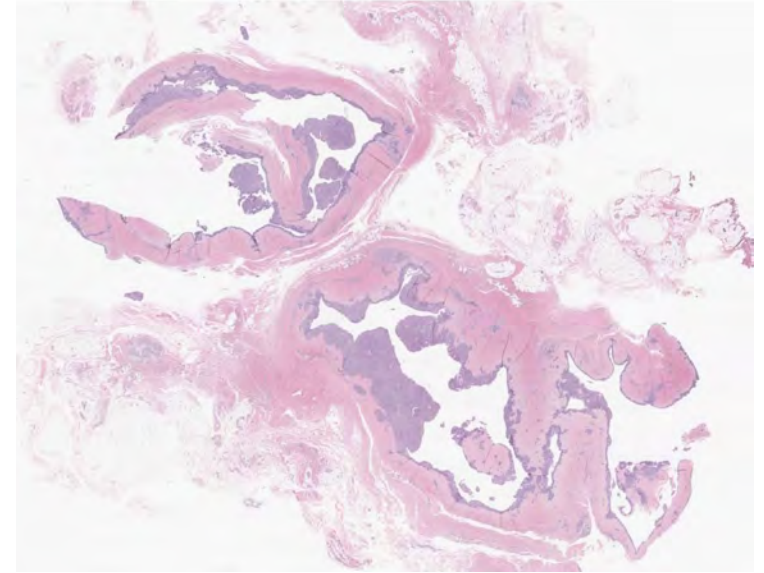


Histopathology



Acral Hidradenoma

- Negative for HPV42
- FISH: MAML2 rearrangement in nearly all tumor cells



MAML2 Rearrangement

MAML2 Fusions in Hidradenoma

GENES, CHROMOSOMES & CANCER 46:559–563 (2007)

Frequent Fusion of the *CRTC1* and *MAML2* Genes in Clear Cell Variants of Cutaneous Hidradenomas

Marta Winnes,¹ Lena Mölne,² Mart Suurküla,² Ywonne Andrén,¹ Fredrik Persson,¹ Fredrik Enlund,¹ and Göran Stenman^{1*}

¹The Lundberg Laboratory for Cancer Research, Department of Pathology, Göteborg University, Sahlgrenska University Hospital, Göteborg, Sweden

²Laboratory of Clinical Pathology and Cytology, Sahlgrenska University Hospital, Göteborg, Sweden



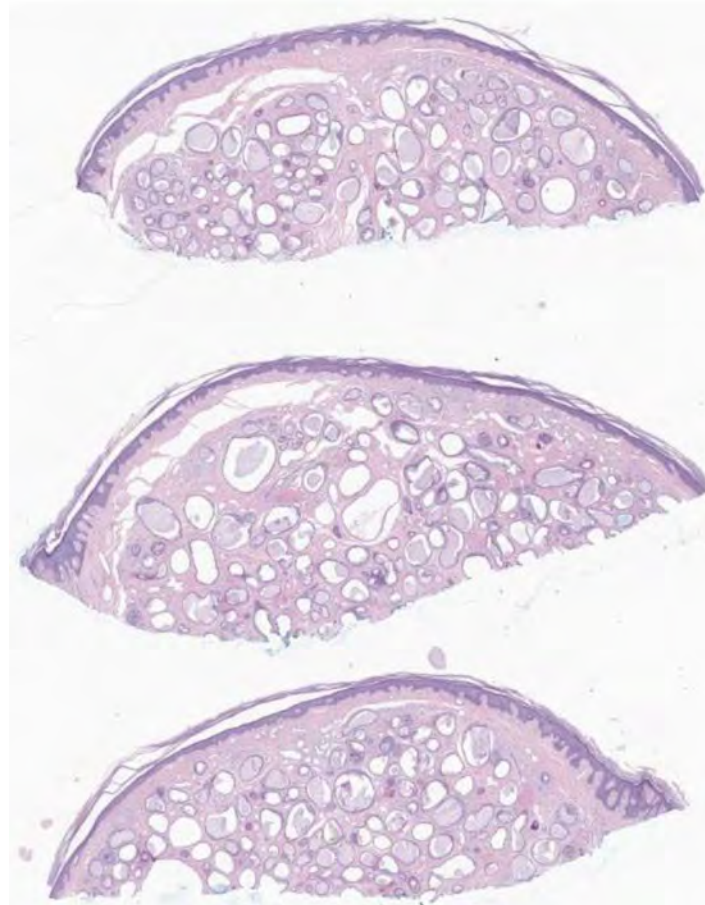
Cutaneous hidradenoma: a study of 21 neoplasms revealing neither correlation between the cellular composition and *CRTC1-MAML2* fusions nor presence of *CRTC3-MAML2* fusions^{☆.☆☆}



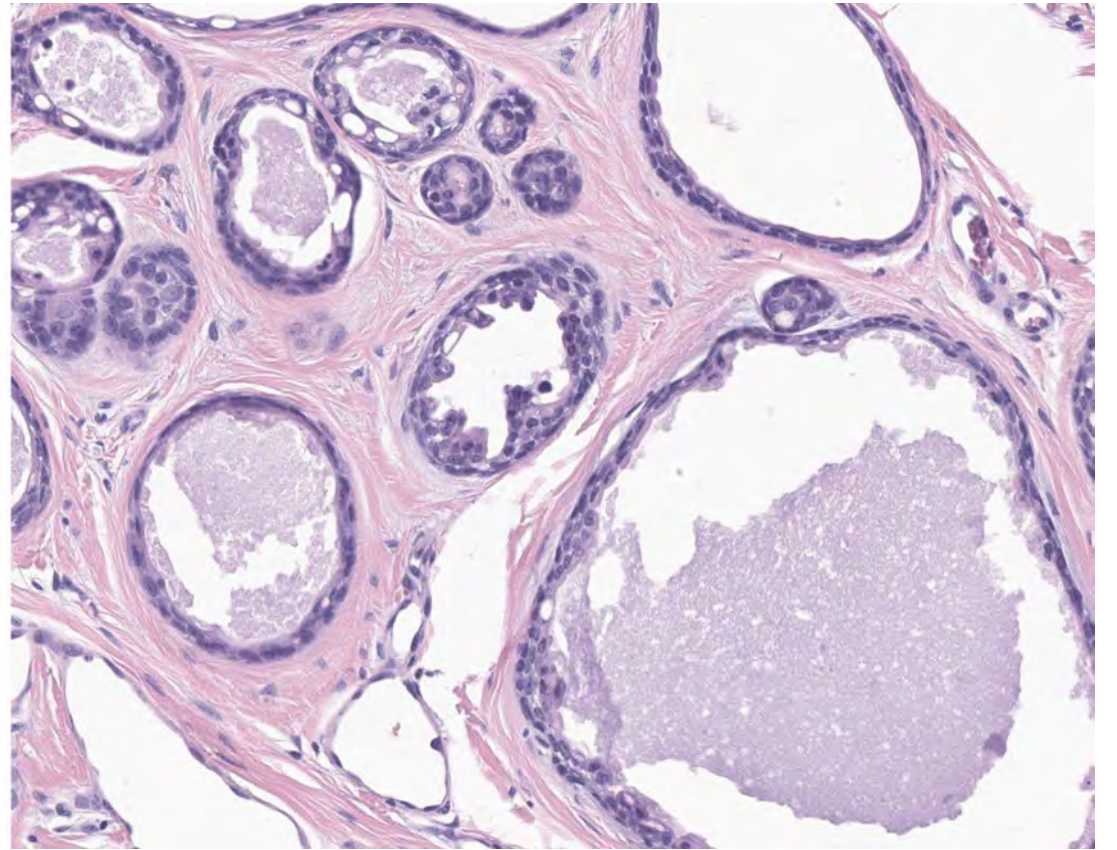
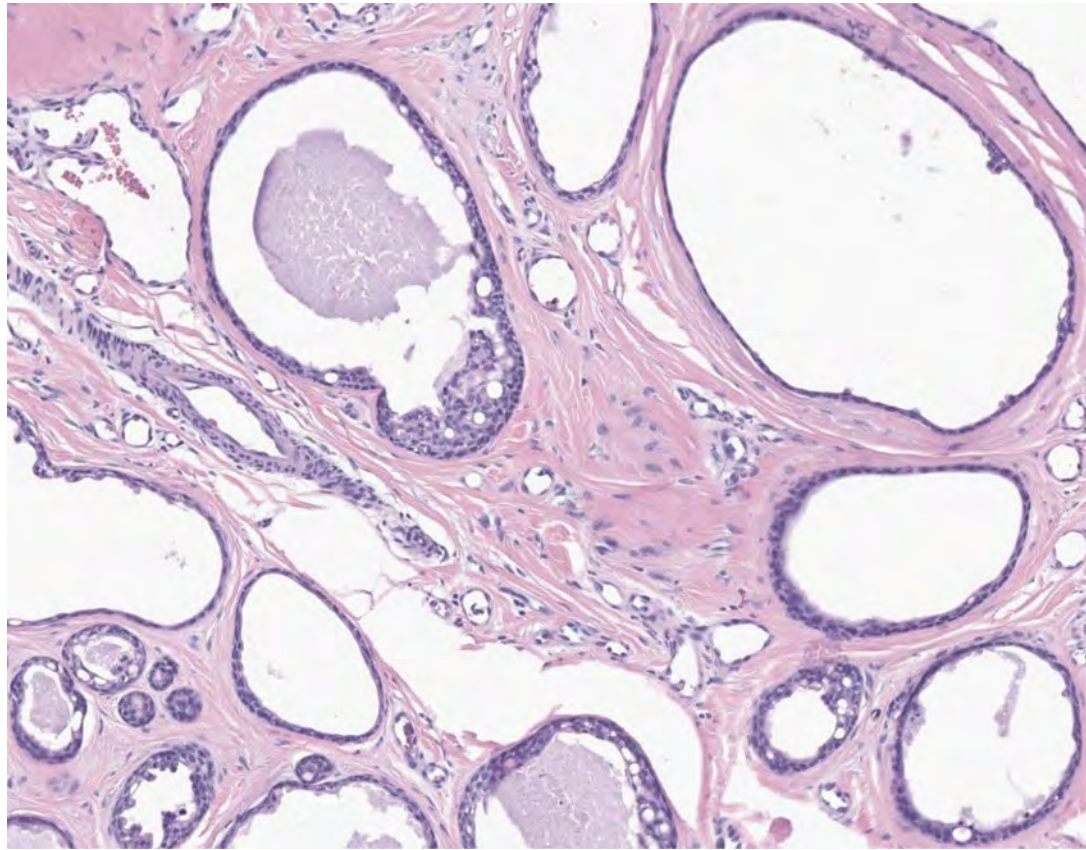
Liubov Kyrpychova, MD^a, Denisa Kacerovska, MD, PhD^{a,b}, Tomas Vanecek, PhD^{a,b}, Petr Grossmann, PhD^{a,b}, Michal Michal, MD^{a,b}, Katrin Kerl, MD^c, Dmitry V. Kazakov, MD, PhD^{a,c,*}

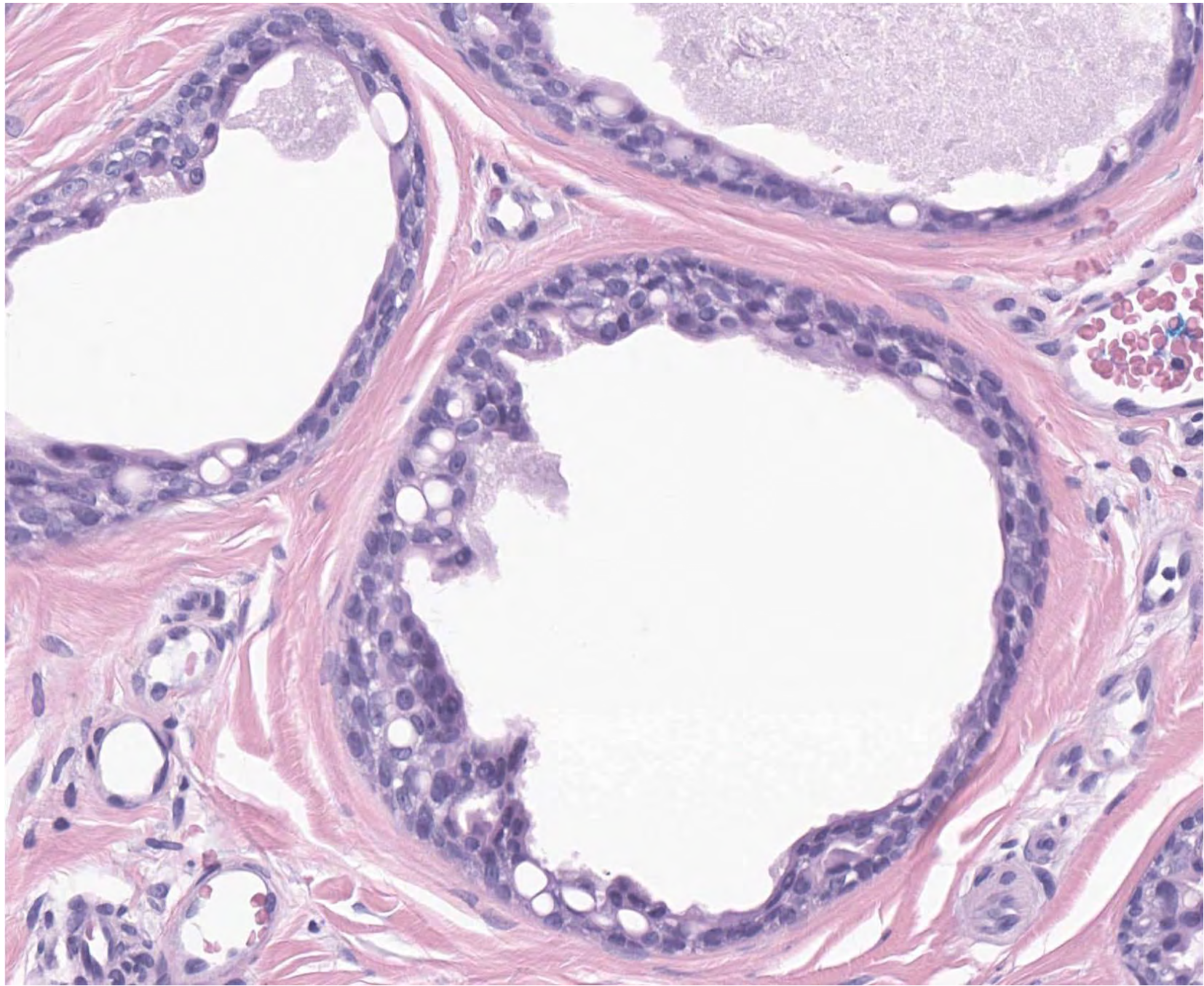
Case 6: What is Your Diagnosis?

- 66F
- Ankle

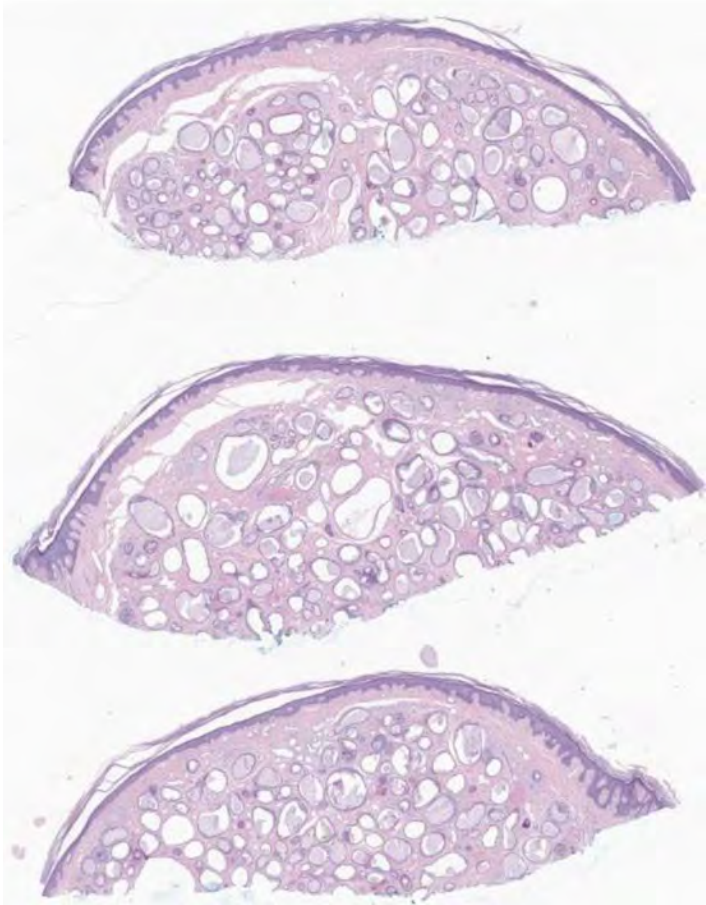


Histopathology





Case 6: Tubular Adenoma



- Test Results

- Negative for HPV42
- Positive for BRAFV600E

Tubulopapillary Adenomas harbor *BRAF* mutations

Human Pathology (2018) 73, 59–65



BRAFV600E Mutation:

- 9/15 (60%) of TAA
- 7/8 (78%) of PEA

Original contribution

***BRAF* and *KRAS* mutations in tubular apocrine adenoma and papillary eccrine adenoma of the skin** ☆, ☆☆



Jau-Yu Liau MD^{a,b,*}, Jia-Huei Tsai MD^{a,b}, Wen-Chang Huang MD^c, Jui Lan MD^d,
Jin-Bon Hong MD^e, Chang-Tsu Yuan MD^a

^aDepartment of Pathology, National Taiwan University Hospital and National Taiwan University College of Medicine, Taipei 10051, Taiwan

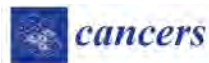^bGraduate Institute of Pathology, National Taiwan University College of Medicine, Taipei 10051, Taiwan

^cDepartment of Pathology, Wan Fang Hospital, Taipei Medical University, Taipei 11696, Taiwan

^dDepartment of Pathology, Kaohsiung Chang Gung Memorial Hospital and Chang Gung University College of Medicine, Kaohsiung 83301, Taiwan

^eDepartment of Dermatology, National Taiwan University Hospital and National Taiwan University College of Medicine, Taipei 10002, Taiwan

Molecular Approach – Gene Fusions



Review

Recent Advances on Immunohistochemistry and Molecular Biology for the Diagnosis of Adnexal Sweat Gland Tumors

Nicolas Macagno ^{1,2,3,*}, Pierre Sohier ^{1,4,5}, Thibault Kervarrec ^{1,6,7}, Daniel Pissaloux ^{8,9}, Marie-Laure Jullie ^{1,10}, Bernard Cribier ^{1,11} and Maxime Battistella ^{1,6,12}

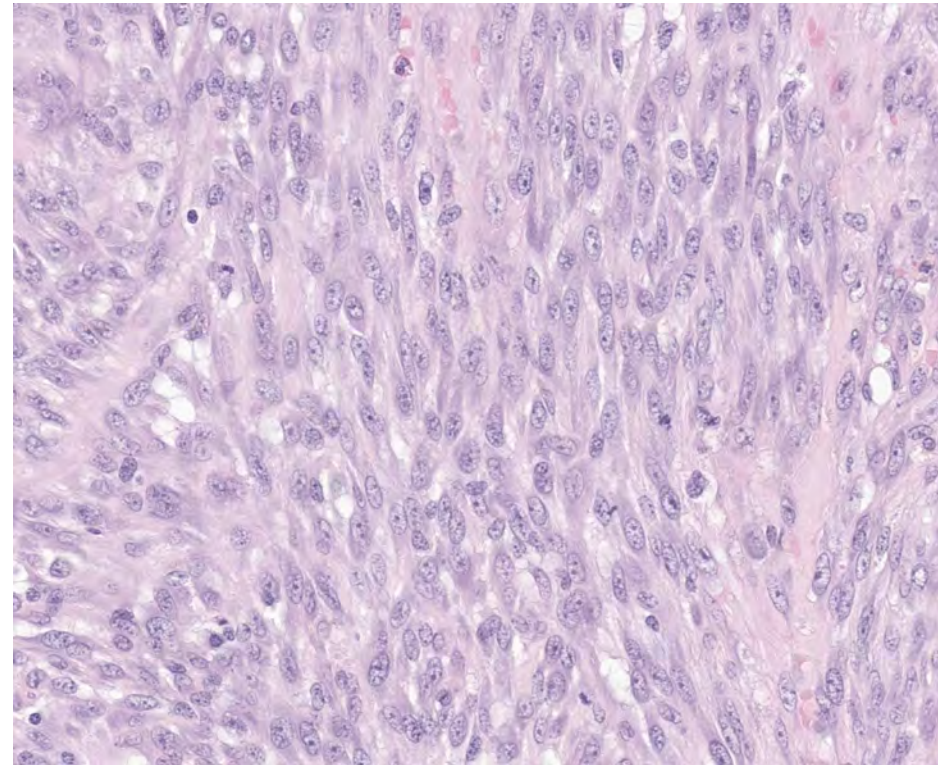
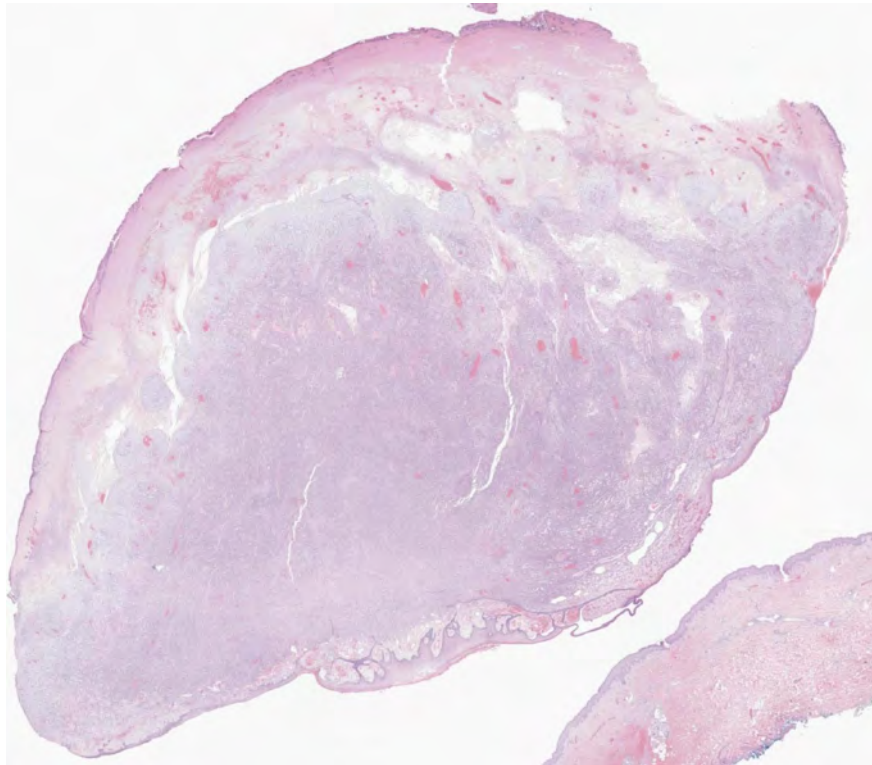
Table 2. Summary of the most frequent molecular alterations in sweat gland neoplasms.

Diagnosis	Molecular Alteration	Frequency (%)
Adenoid cystic carcinoma	<i>MYB::NFIB</i> fusion	73–83%
	<i>MYBL1::NFIB</i> fusion	20–23%
Cutaneous mixed tumor	<i>PLAG1</i> fusion	33%
	<i>HMGA2</i> fusion	unknown
Cylindroma	<i>CYLD</i> inactivation	near 100%
Spiradenoma	<i>CYLD</i> inactivation	29%
	<i>ALPK1</i> p.V1092A mutation	43%
Spiradenocarcinoma	<i>CYLD</i> inactivation	8%
	<i>ALPK1</i> p.V1092A mutation	33%
Hidradenoma	<i>CRTC1::MAML2</i> fusion	50–75%
	<i>CRTC3::MAML2</i> fusion	rare
Hidradenocarcinoma	<i>CRTC1::MAML2</i> fusion	unknown
Myoepithelioma	<i>EWSR1</i> fusion	82%
	<i>FUS</i> fusion	18%
Poroma	<i>YAP1</i> fusion	88%
	<i>NUTM1</i> fusion	17–55%
Porocarcinoma	<i>YAP1</i> fusion	8–63%
	<i>NUTM1</i> fusion	11–54%
Secretory carcinoma	<i>ETV6::NTRK3</i> fusion	near 100%
Syringocystadenoma papilliferum and tubular adenoma	<i>BRAF</i> p.V600E mutation	50–64%
	<i>HRAS</i> p.G13R mutation	7–26%
	<i>KRAS</i> p.G12D mutation	rare

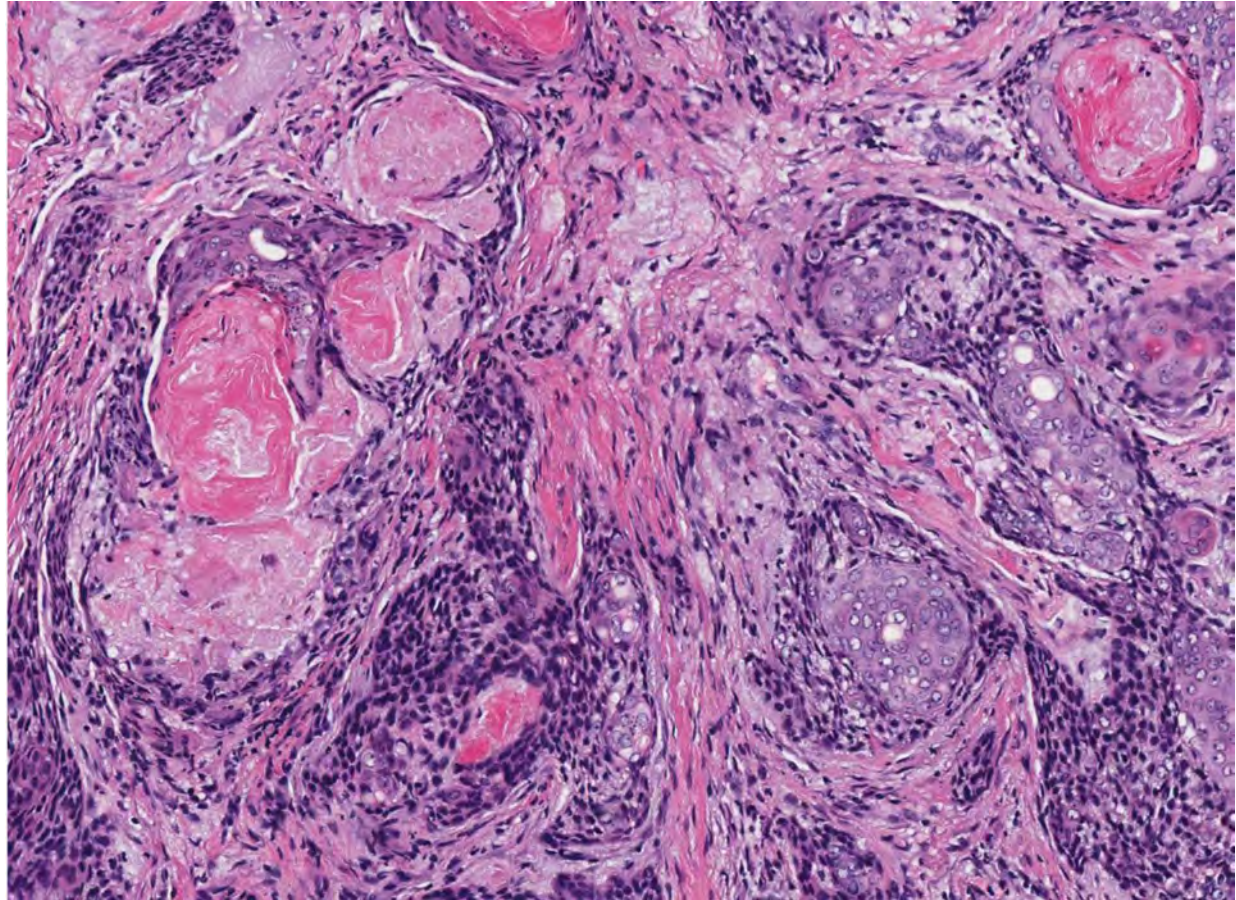
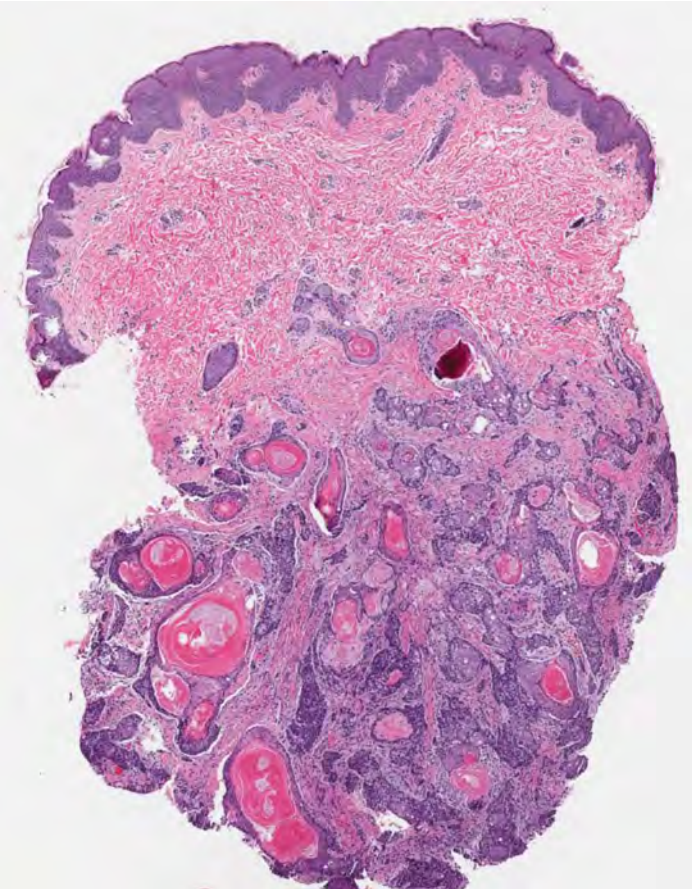CASE STUDY

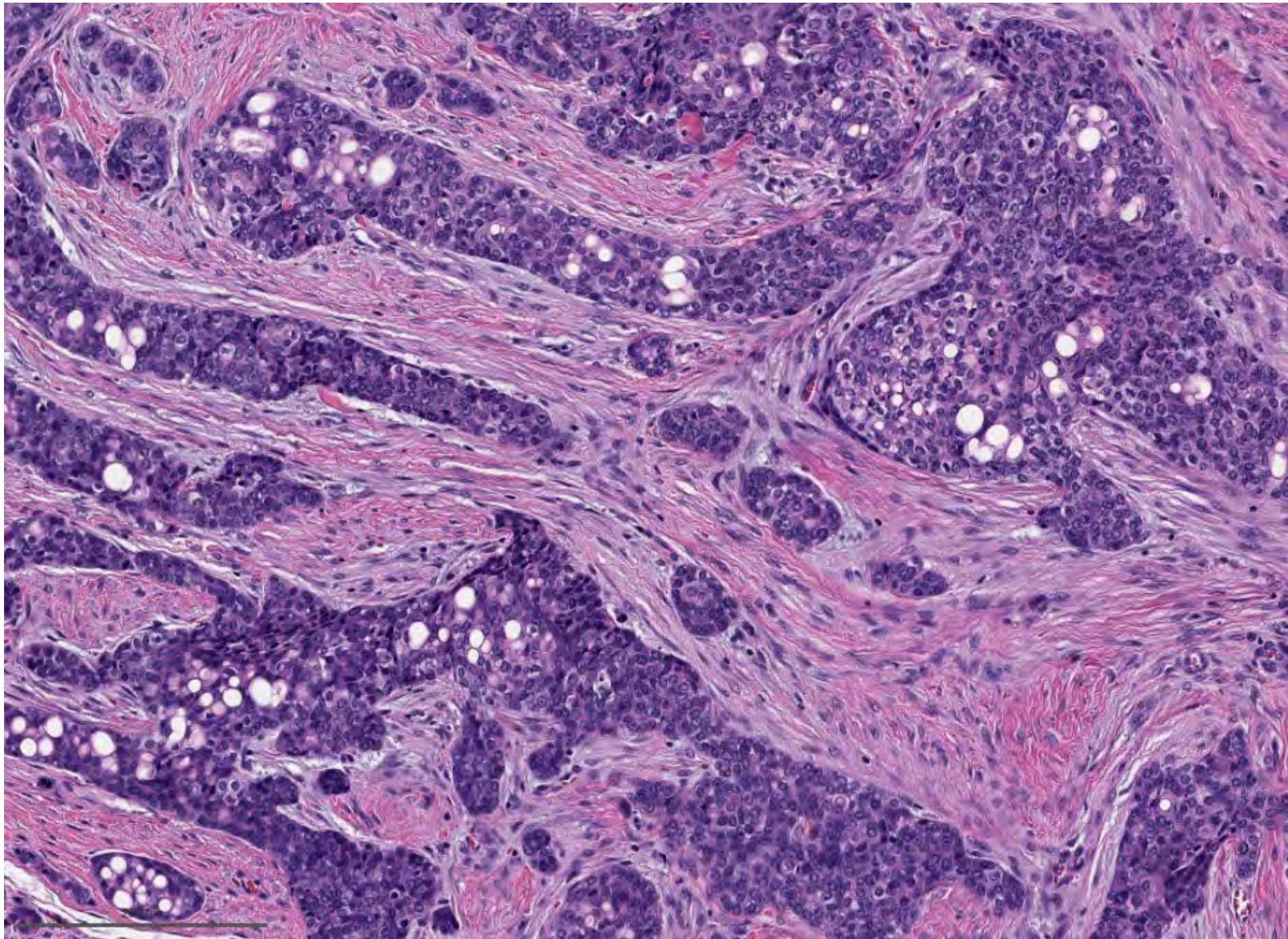
Spindle cell porocarcinoma with a novel *YAP1::MAML3* fusion

Philippa Li MD¹ | Klaus J. Busam MD² 

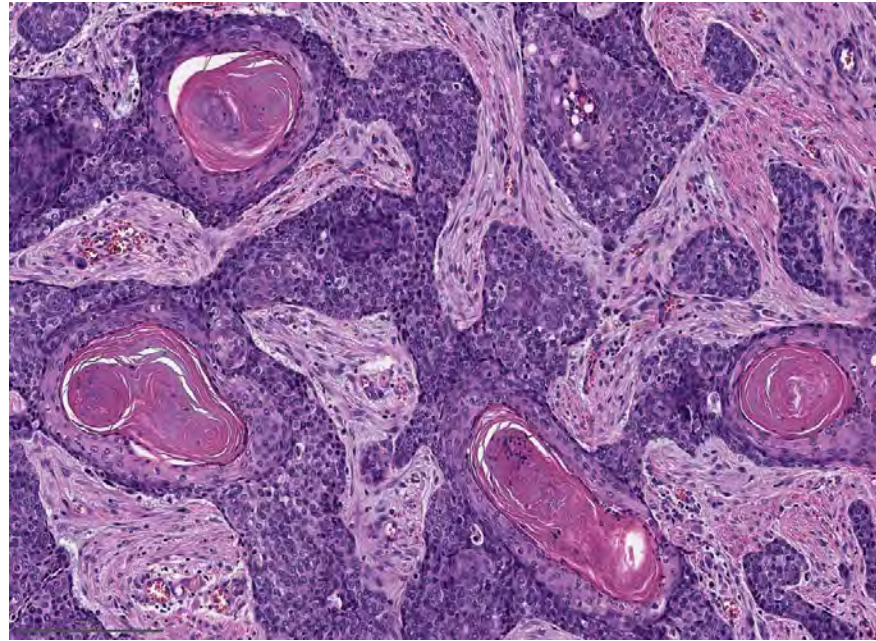
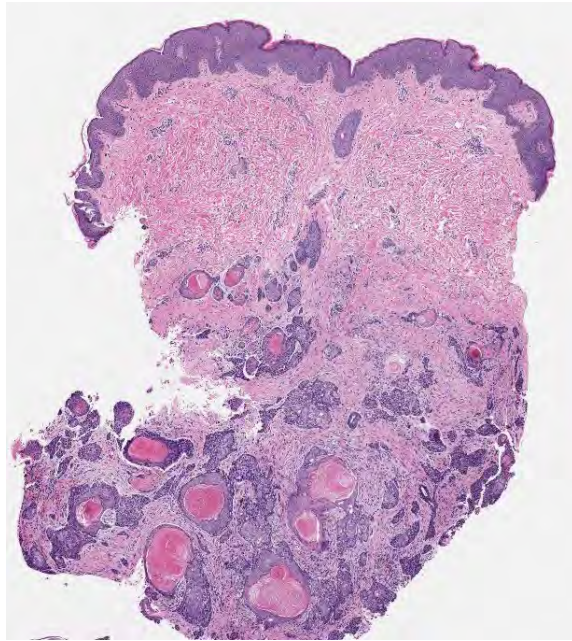


Case 7: 7 F, shoulder





Diagnosis: NUT Adnexal Carcinoma (NAC)



Published in final edited form as:

J Cutan Pathol. 2021 December ; 48(12): 1508–1513. doi:10.1111/cup.14107.

Skin Adnexal Carcinoma with BRD3-NUTM2B Fusion

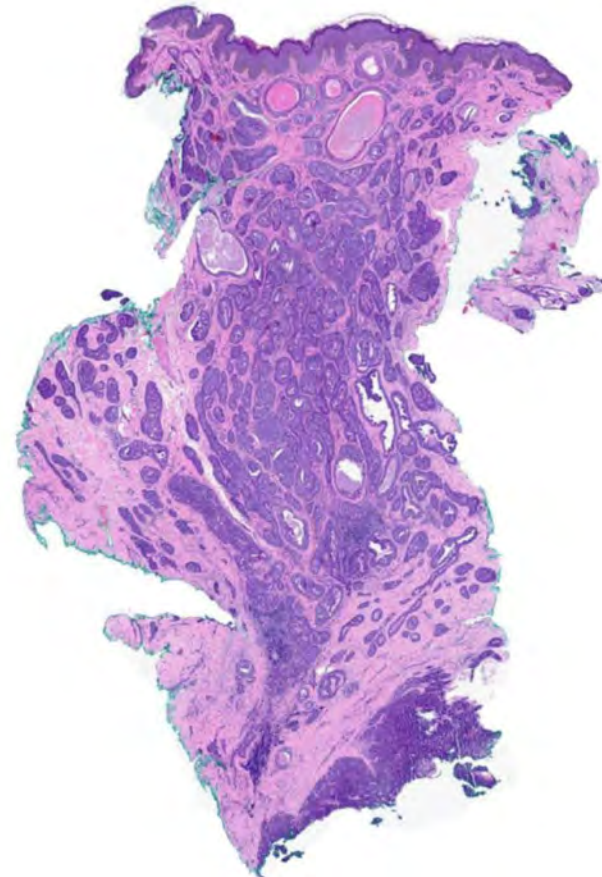
Belen Rubio Gonzalez, MD¹, Michael V Ortiz, MD², Dara S Ross, MD¹, Klaus J Busam, MD¹

¹Departments of Pathology and Memorial Sloan Kettering Cancer Center, New York, NY 10065

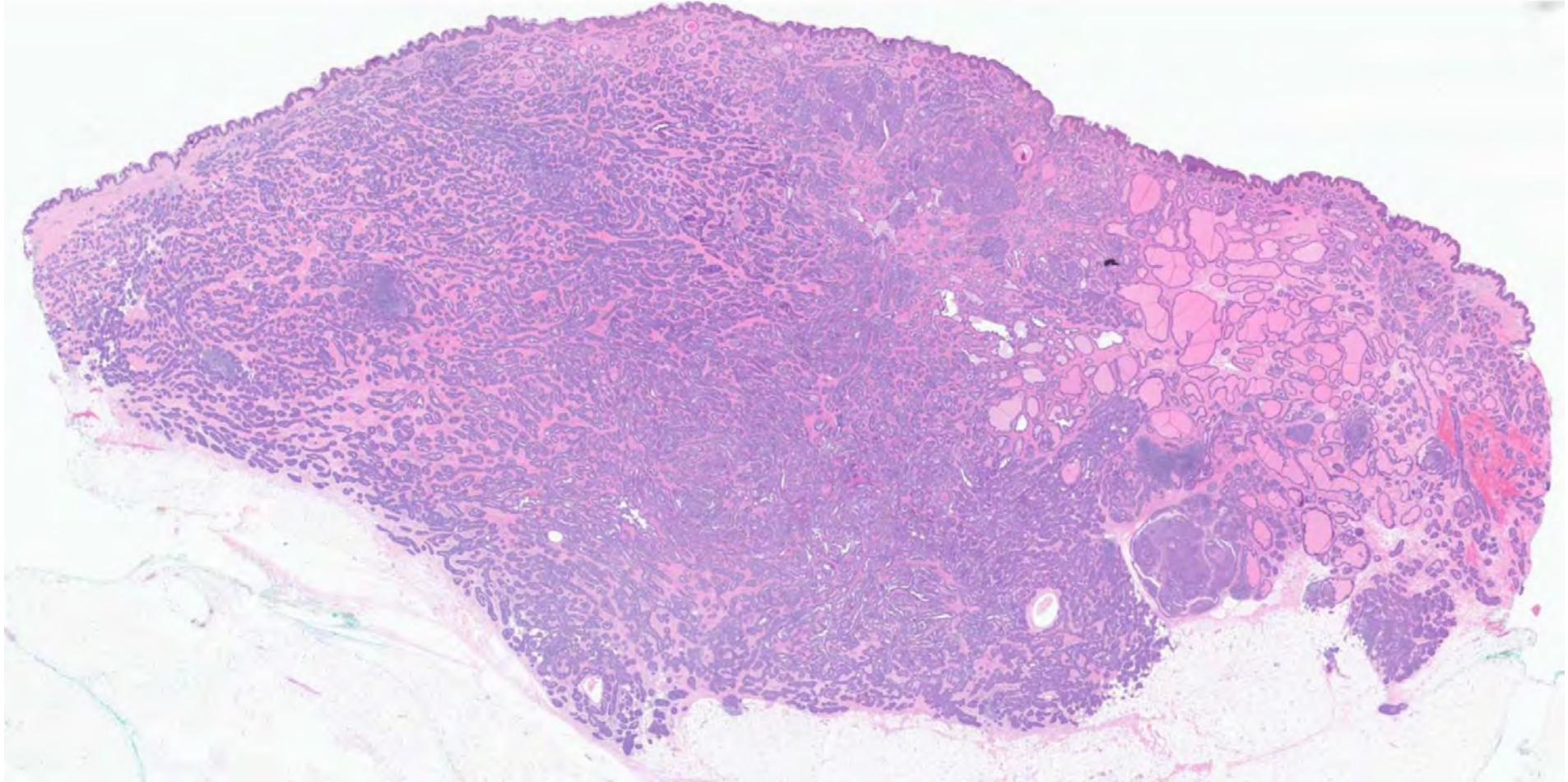
²Pediatrics, Memorial Sloan Kettering Cancer Center, New York, NY 10065

Case 8: 28 F with arm nodule

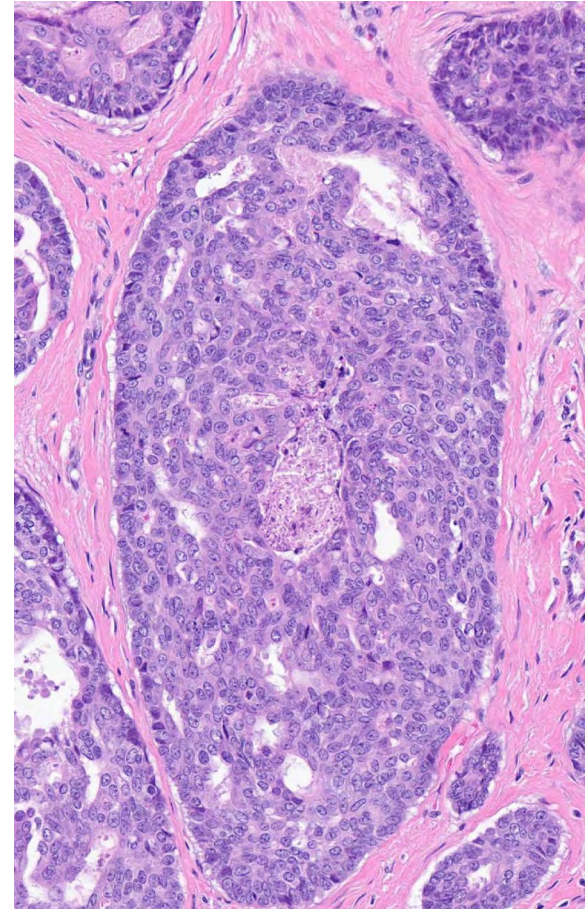
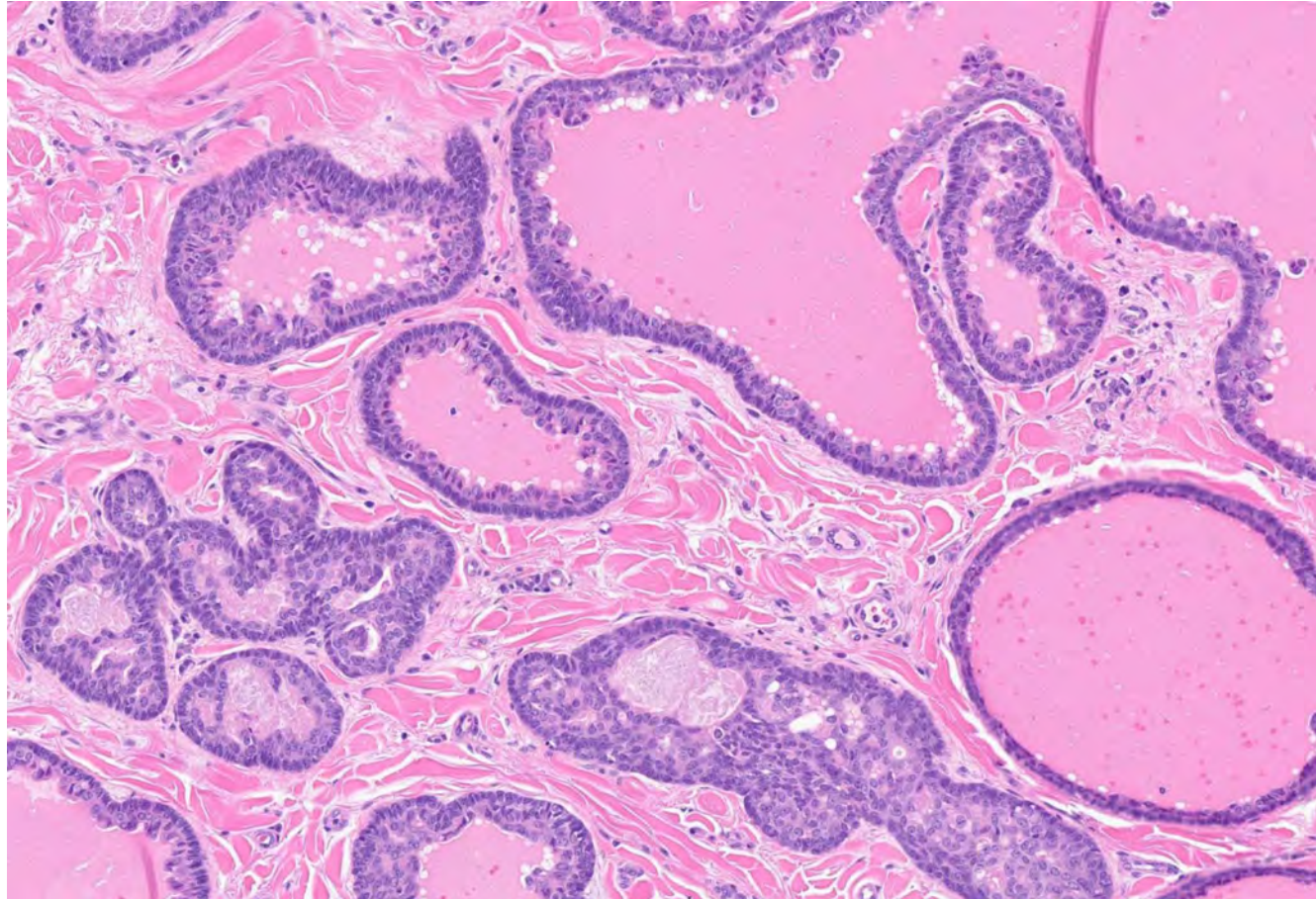
- Shave biopsy 13 years earlier
“benign adnexal neoplasm”
- Tumor grew in past 2 years
- Punch biopsy



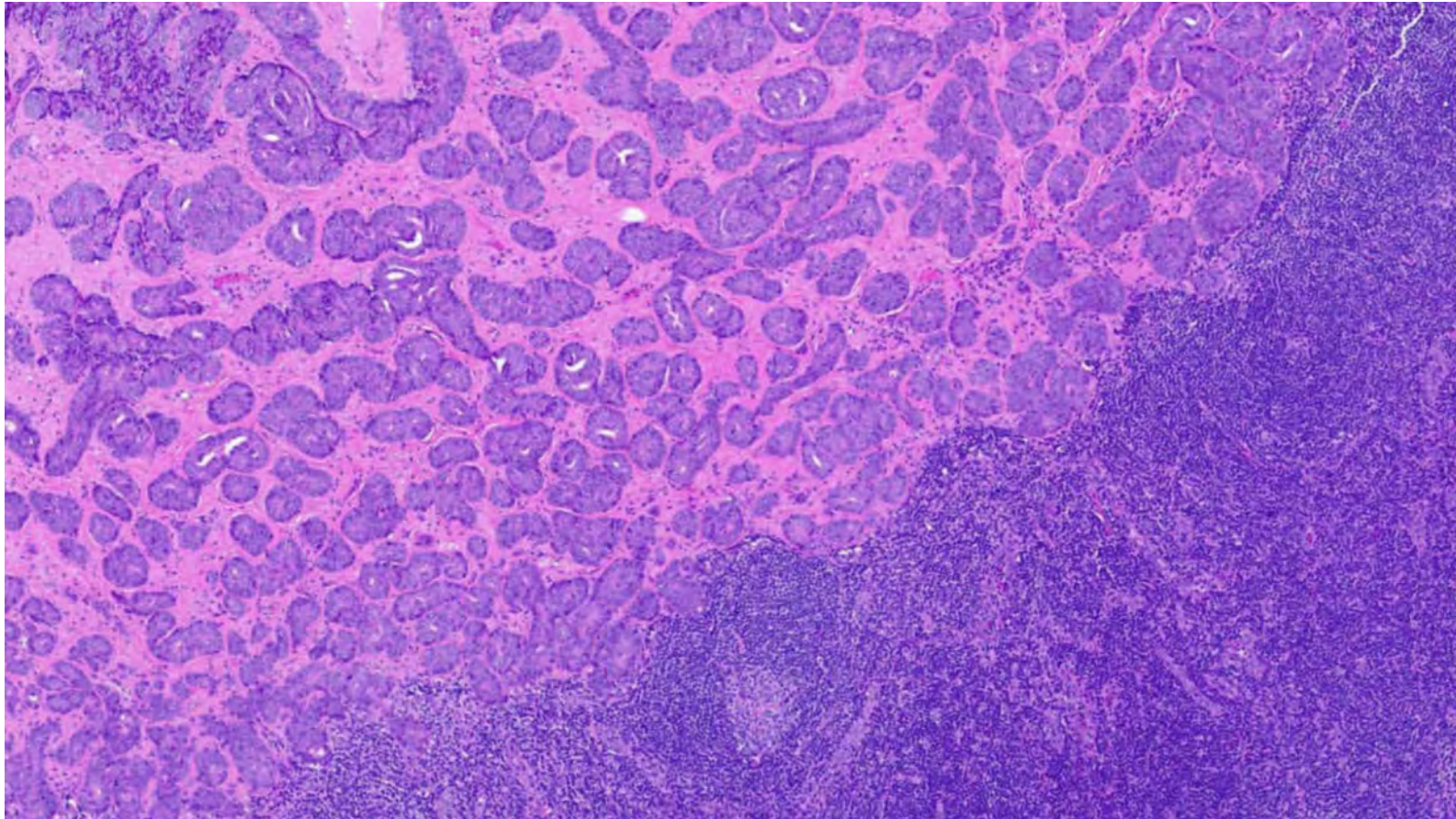
Case 8: 28 F with arm nodule



Case 8: 57 F with forearm nodule



Case 8: Positive SLN



Case 8: NUT Adnexal Carcinoma

- Microscopic features of epithelial/myoepithelial carcinoma
- Clinically a primary dermal neoplasm
- Molecular test result **BRD3::NUTM1**

NUT Adnexal Carcinoma



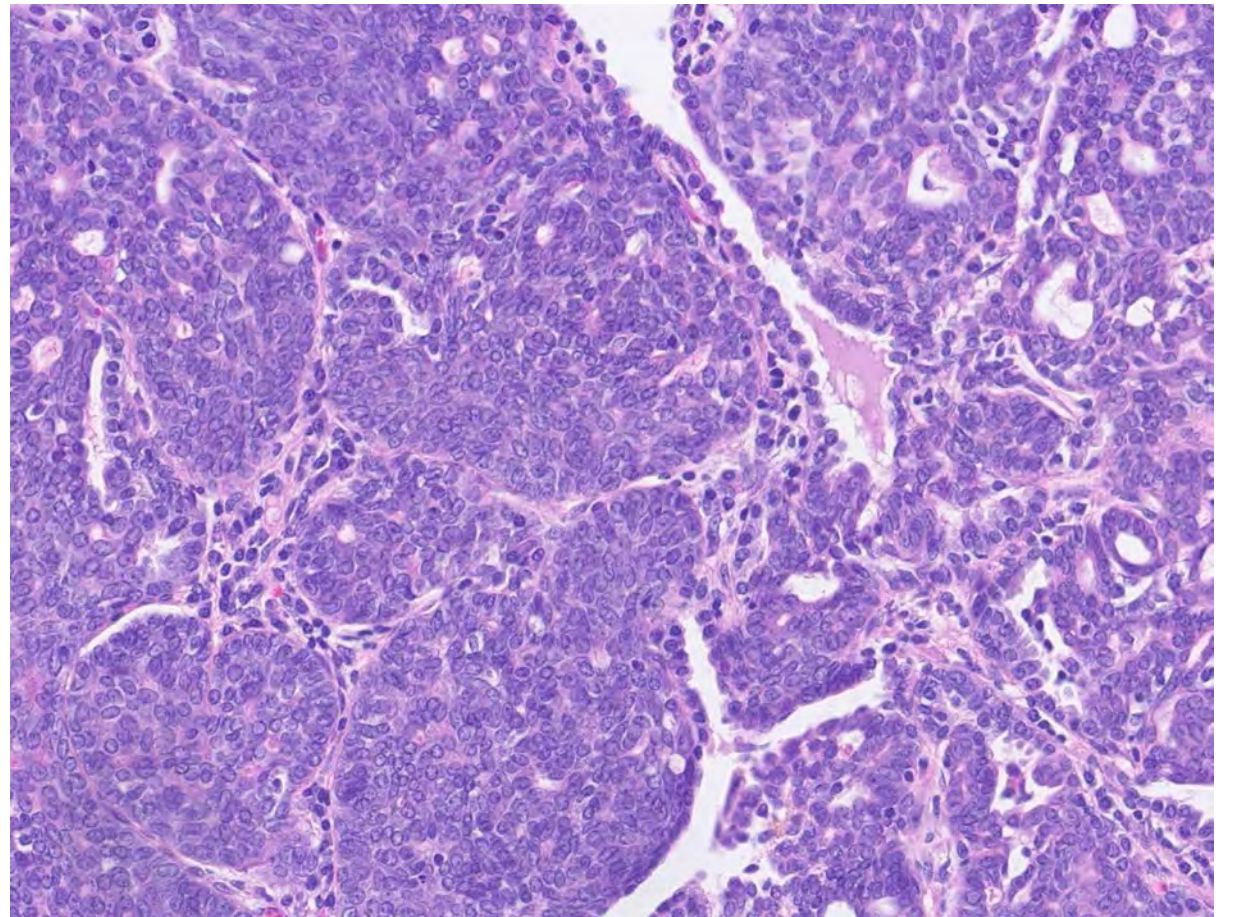
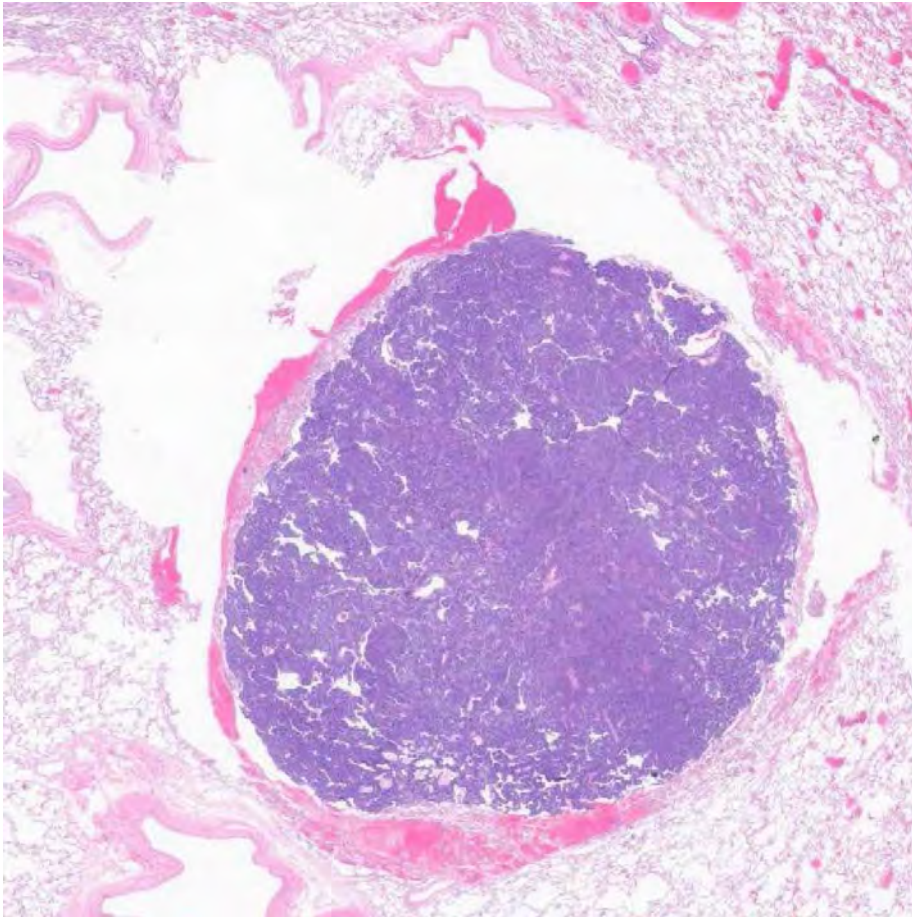
Histopathology 2025 DOI: 10.1111/his.15444

Primary cutaneous NUT adnexal carcinoma: morphologic, genetic and methylation analysis of seven new cases with comparison to extracutaneous NUT carcinoma and *NUTM1*-rearranged porocarcinoma

Mélanie Legrand,¹ Baptiste Louveau,^{2,3,4} Amélie Osio,^{5,6} Anne Tallet,⁷ Eduardo Calonje,⁸ Jean-Yves Scoazec,⁹ Arnaud de la Fouchardiere,^{10,11} Franck Tirode,^{10,11} Andreas Von Deimling,¹² Klaus Busam,¹³ Ahmed Shah,¹⁴ Ashley Flaman,¹⁴ Fanélie Jouenne,^{2,3,4} Samia Mourah,^{2,3,4} Daniel Pissaloux,¹⁵ Sylvie Lantuejoul,¹⁰ Christopher A French,¹⁶ Keisuke Goto,^{17,18,19,20} Bernard Cribier,^{21,22} Carina A Dehner,²³ Ahmed K Alomari,²⁴ Christopher DM Fletcher,²⁵ John Hanna,²⁵ Nicolas Macagno,^{21,26} Maxime Battistella^{5,21} & Thibault Kervarrec^{1,21,27}

- Spectrum of phenotypes
- Spectrum of gene Fusions
 - BRD3::*NUTM1*
 - BRD3::*NUTM2B*
 - BRD4::*NUTM1*
 - NSD3::*NUTM1*

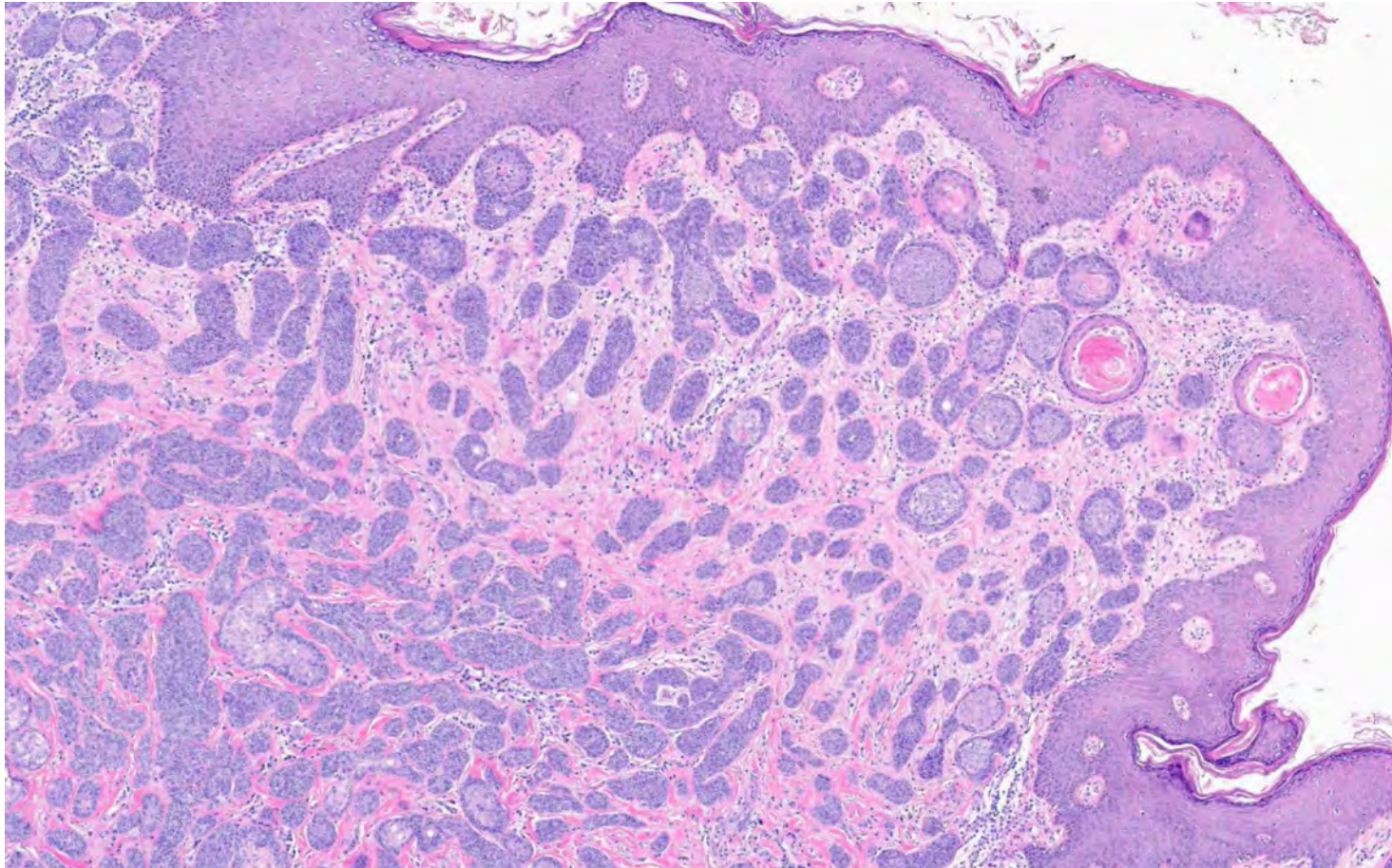
Case 9 : 47 F, Lung Tumor



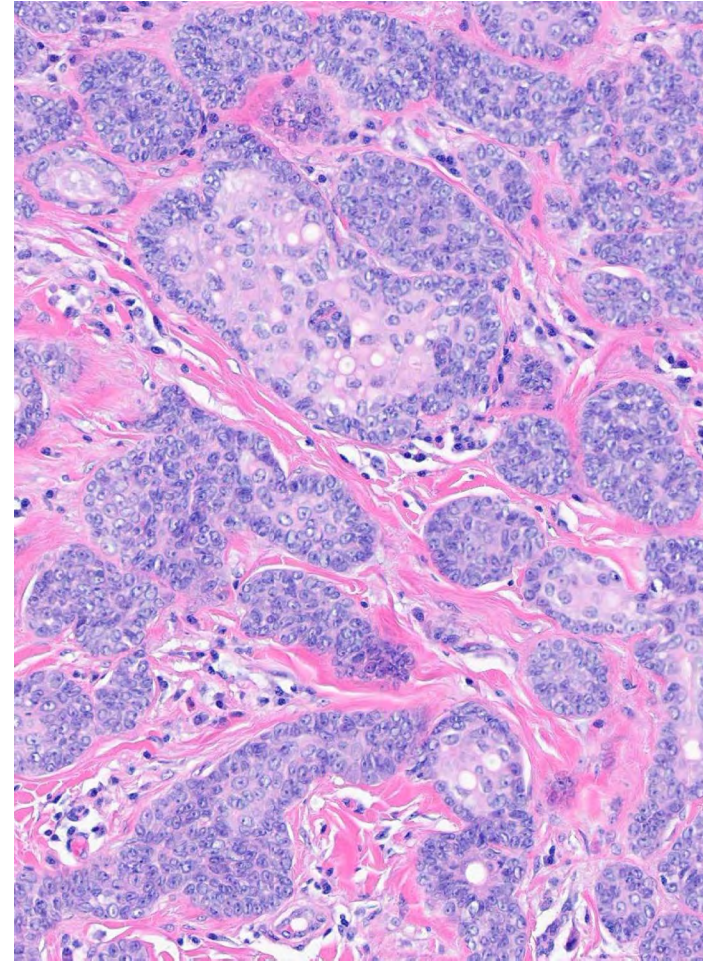
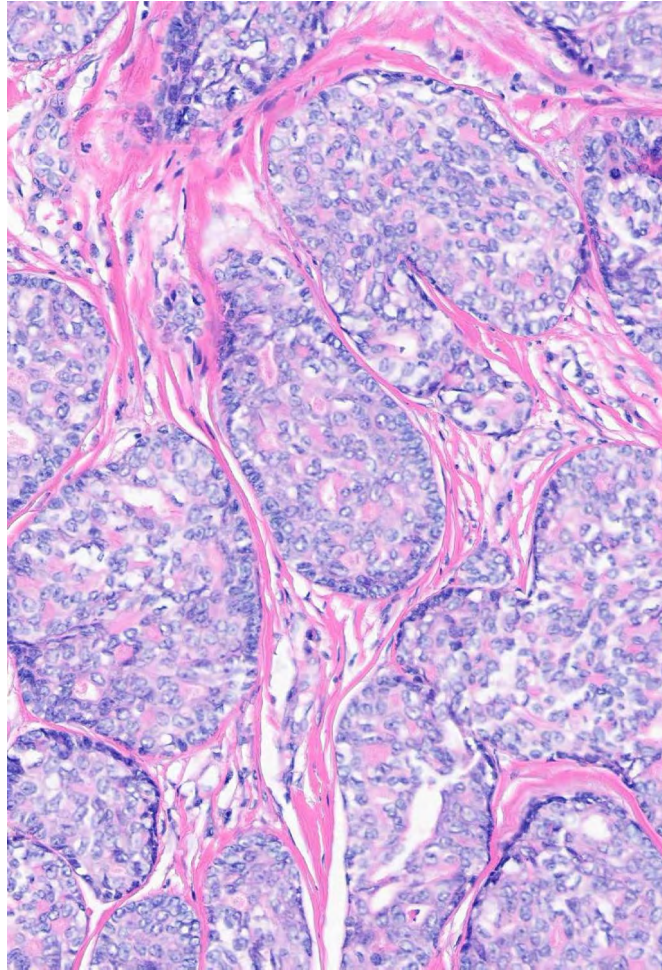
Molecular Test Result

BRD3::NUTM1

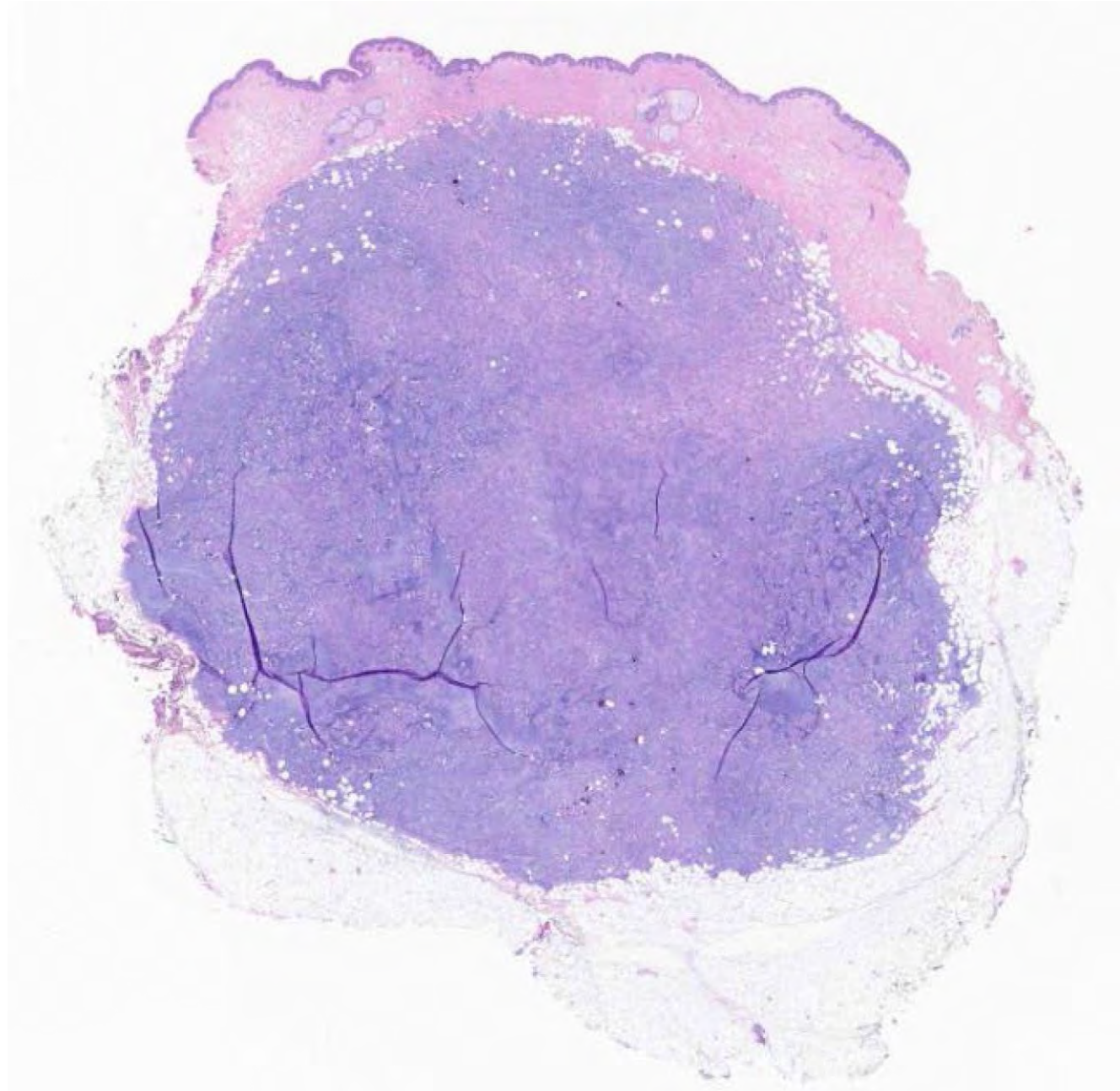
12 years earlier – thigh nodule

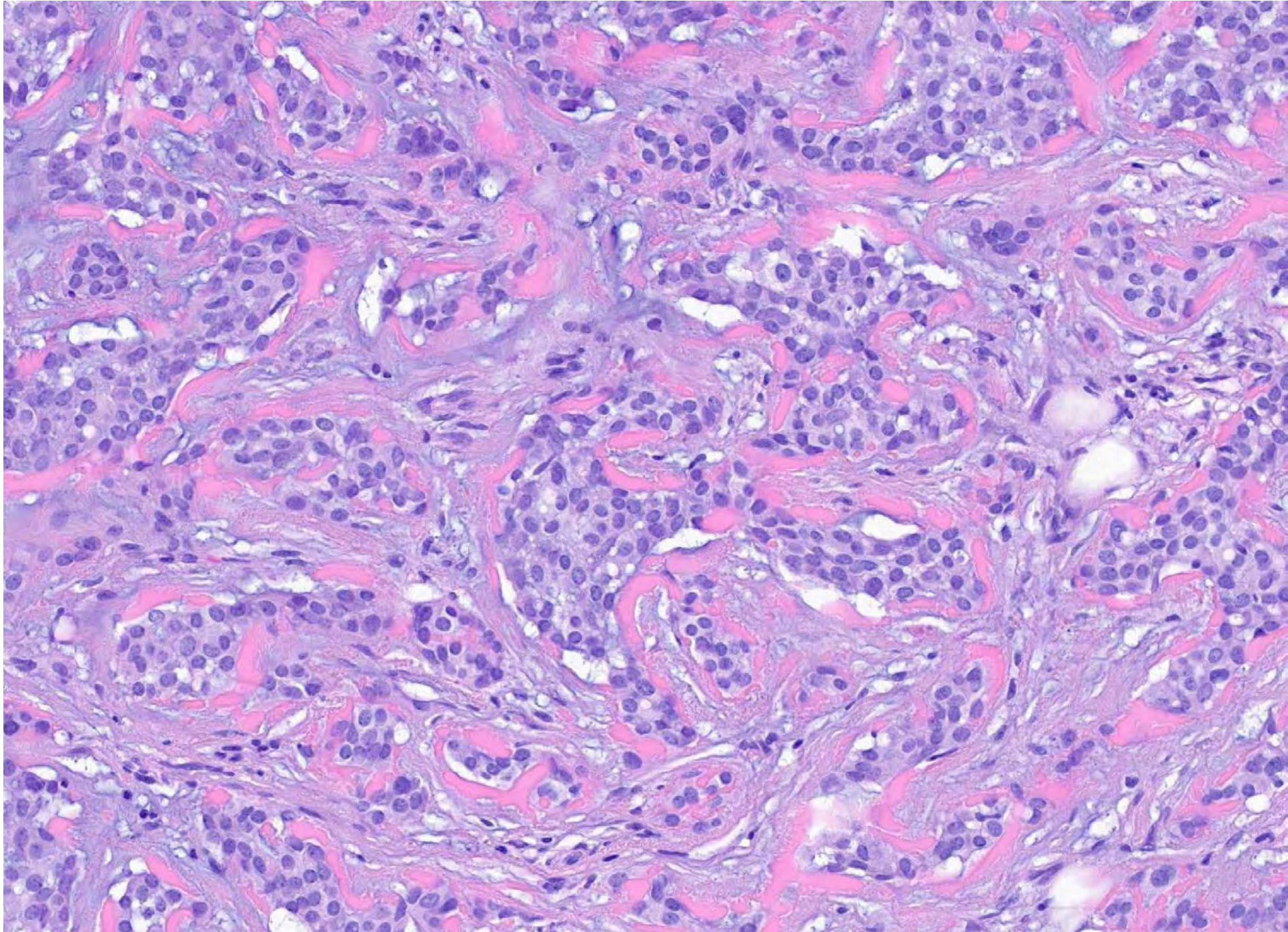


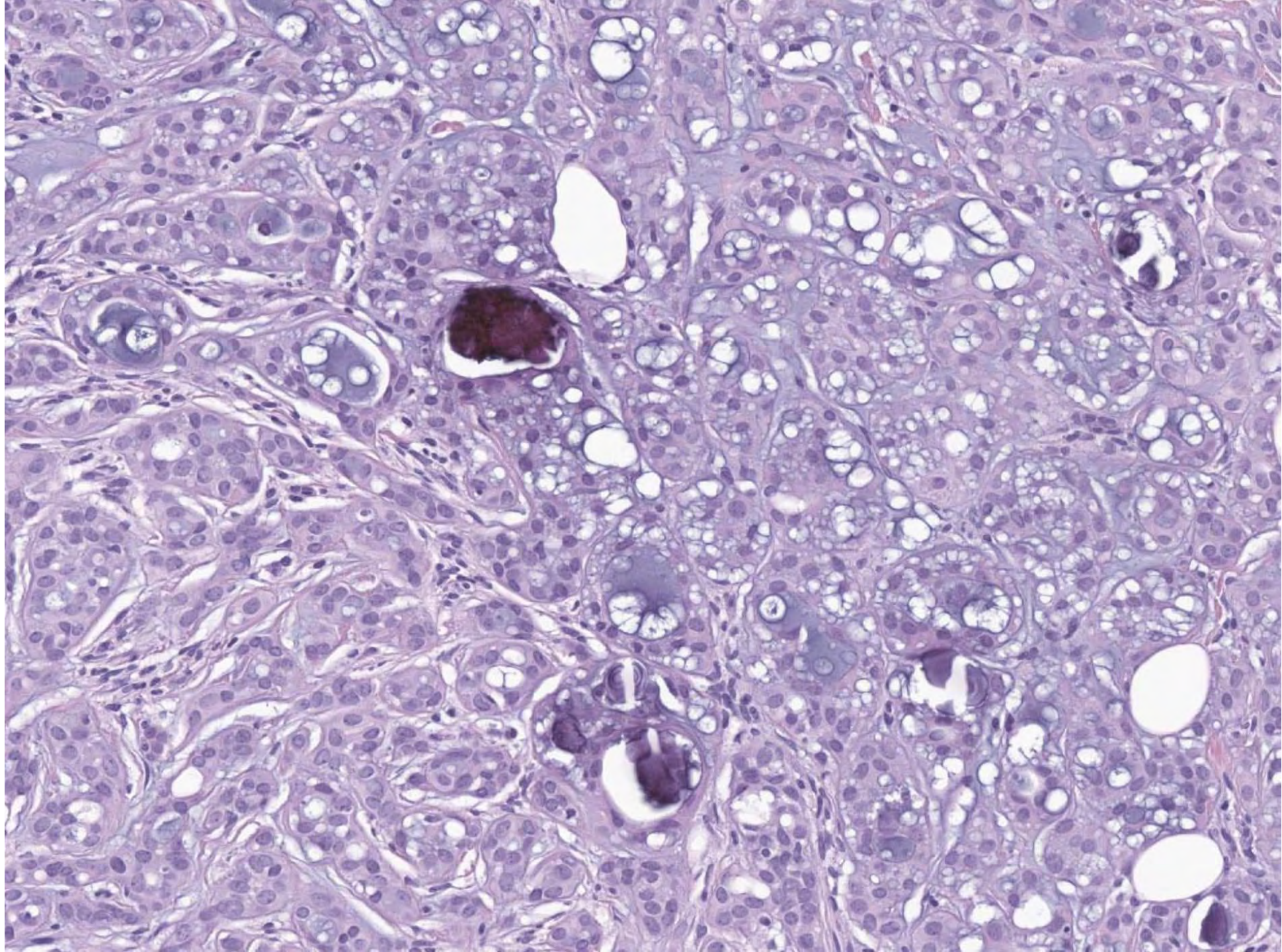
NUT Adnexal Carcinoma (BRD3::NUTM1)

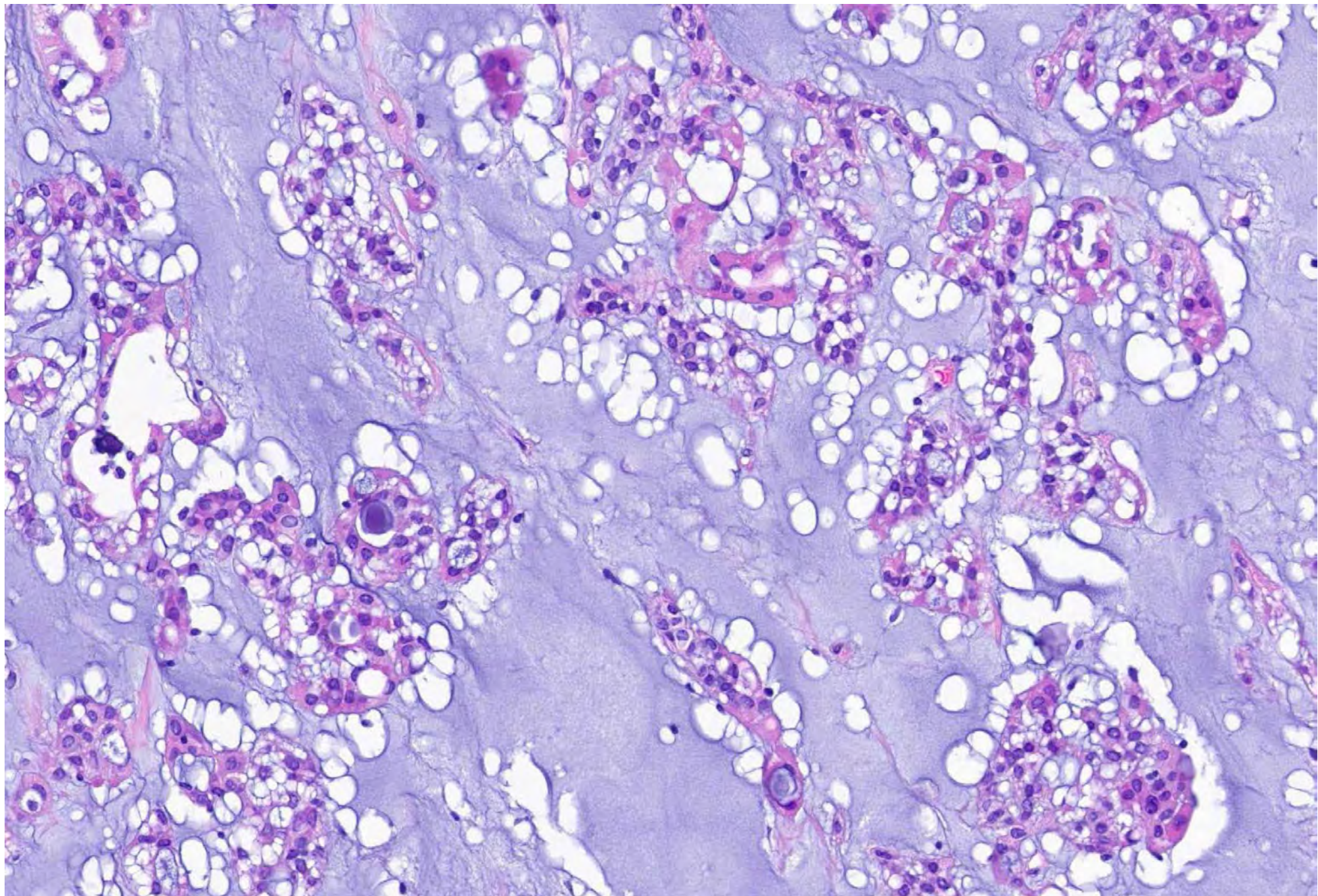


Case 10:
70 F, Chest

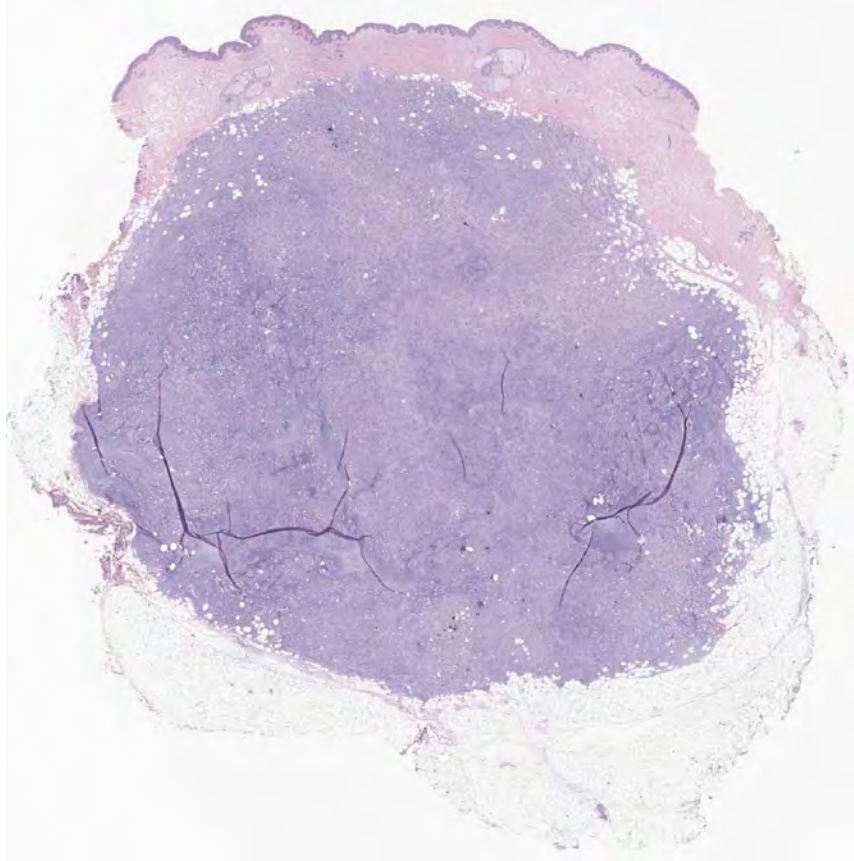








Case 10 : Microsecretory Adenocarcinoma



Nodule on chest wall

Molecular Test Result:

- MEF2C::SS18

DX: Microsecretory Adenocarcinoma

Check for updates

Received: 29 April 2022 | Revised: 27 May 2022 | Accepted: 6 June 2022
DOI: 10.1111/cup.14271

ORIGINAL ARTICLE

Microsecretory adenocarcinoma of the skin harboring recurrent *SS18* fusions: A cutaneous analog to a newly described salivary gland tumor

Justin A. Bishop¹ | Erik A. Williams² | Anne C. McLean¹ | Jeffrey Gagan¹ |
Lisa M. Rooper³ | Richard C. K. Jordan² | Philip E. LeBoit²

Received: 18 August 2022 | Revised: 26 September 2022 | Accepted: 15 October 2022
DOI: 10.1111/cup.14349

PERSPECTIVE

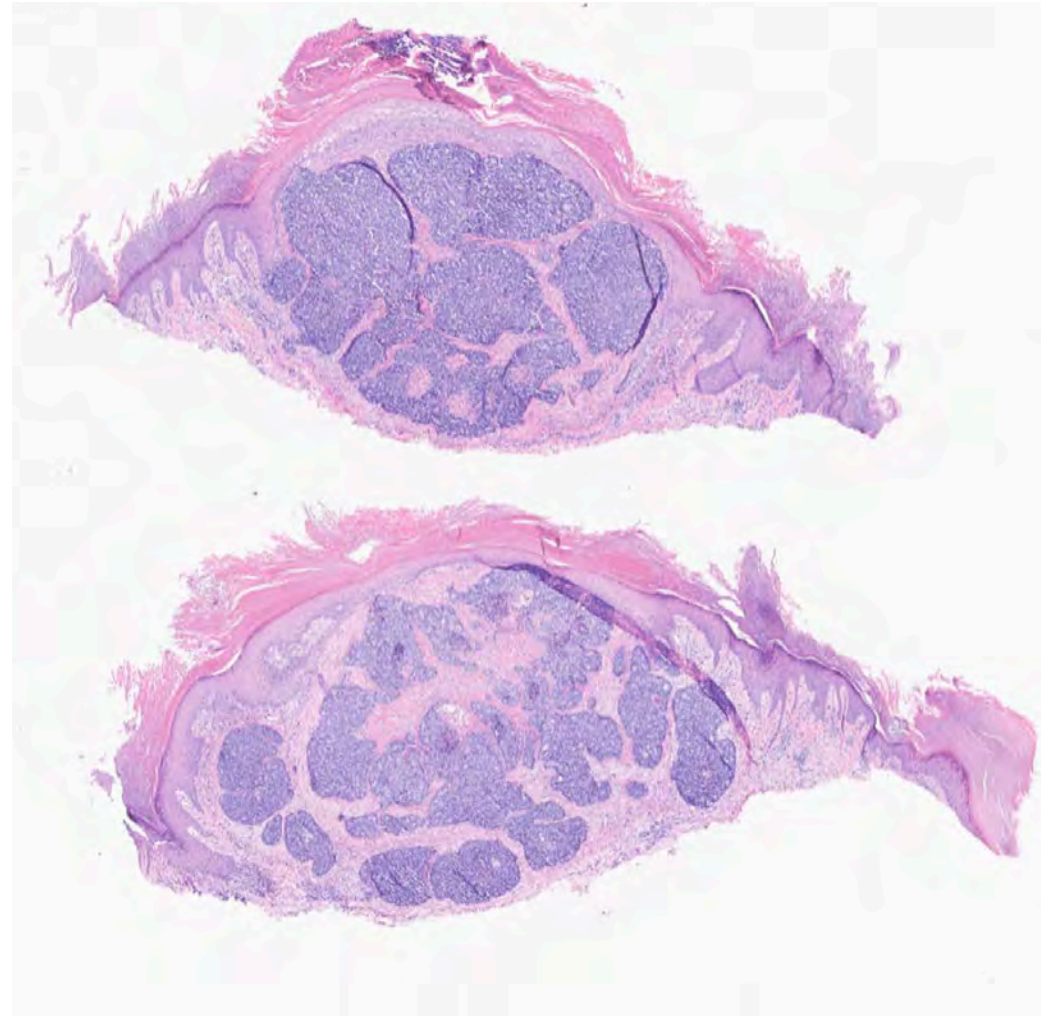
Microsecretory adenocarcinoma: Cutaneous counterpart of a newly described salivary gland tumor with recurrent *MEF2C::SS18* fusion

Gauri Panse MD^{1,2}

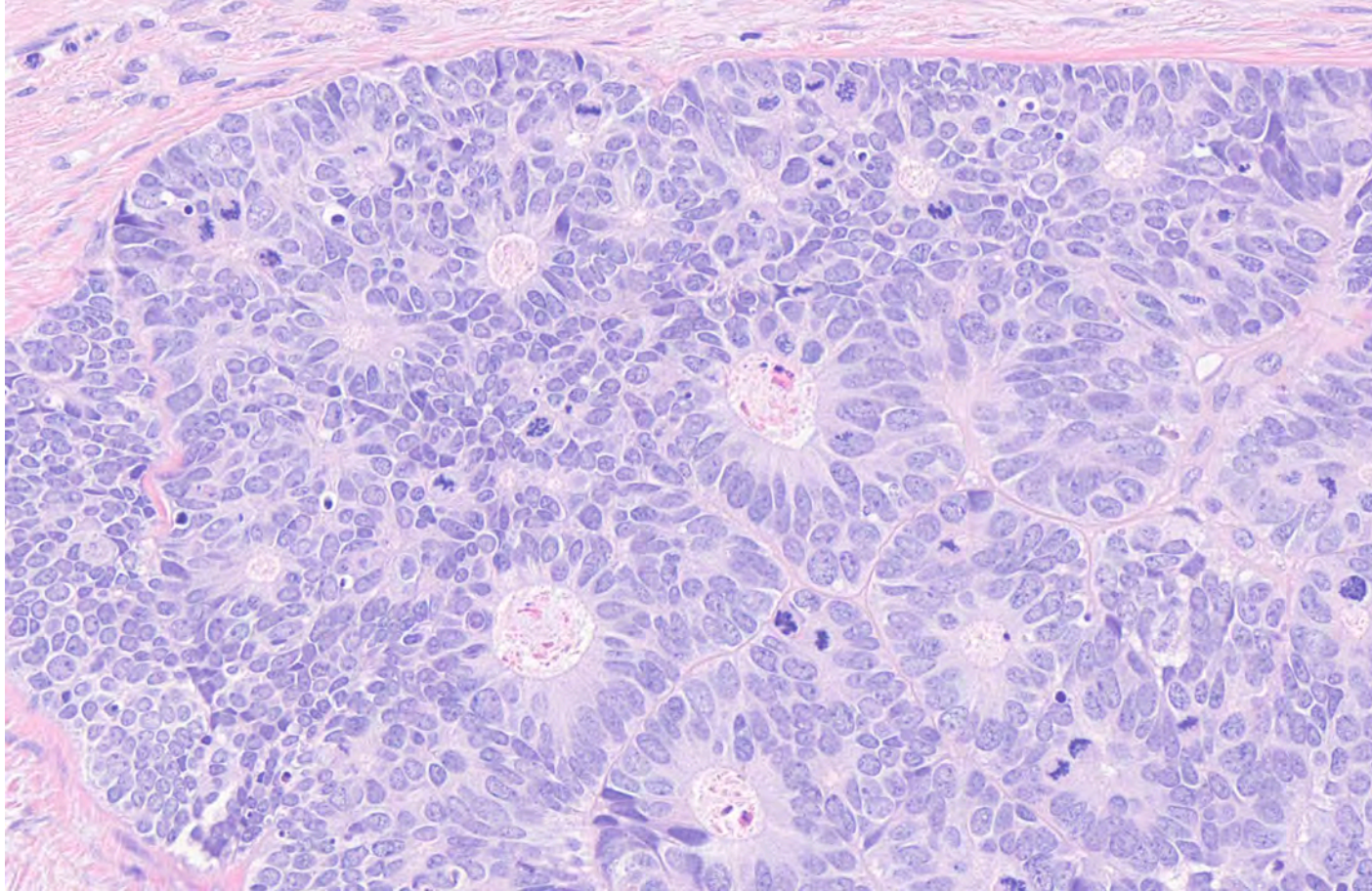
Lessons from cases 5 - 10

- Molecular findings can be useful for the diagnosis of sweat gland carcinomas
- NUT adnexal carcinoma is an emerging entity comprising a spectrum of previously difficult to classify tumors
- Molecular analysis is helpful for challenging cases

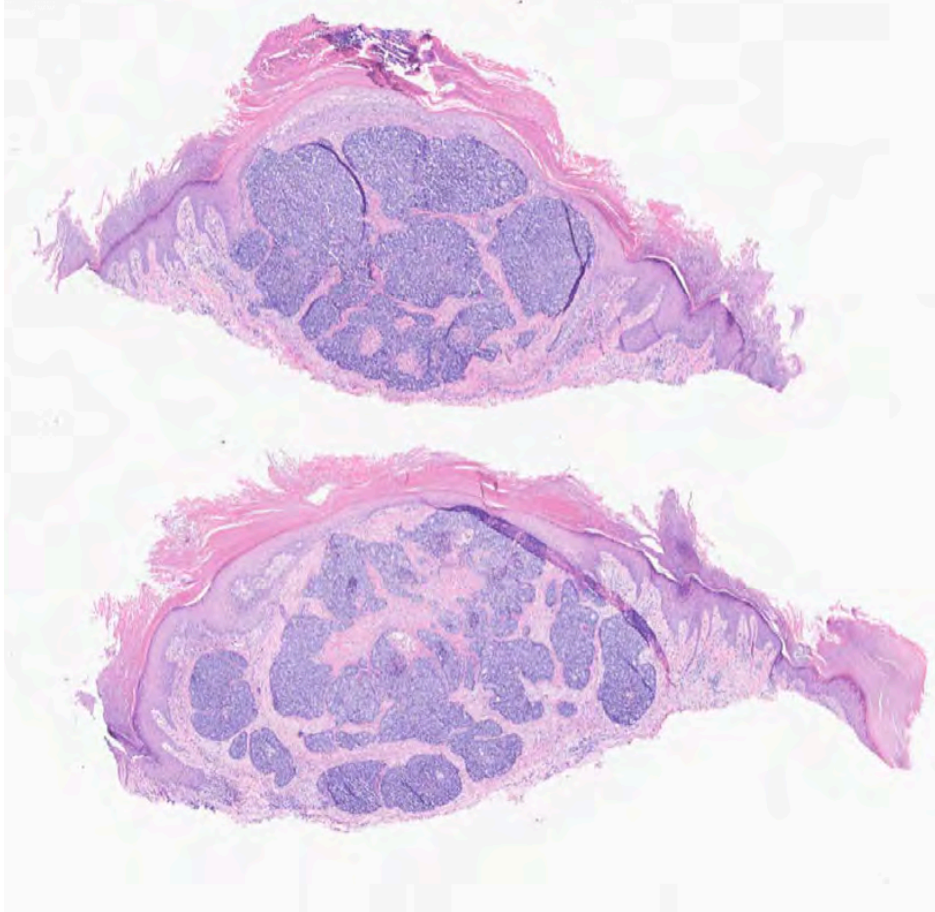
Case 11: 57 F with forearm nodule



Case 11: 57 F with forearm nodule

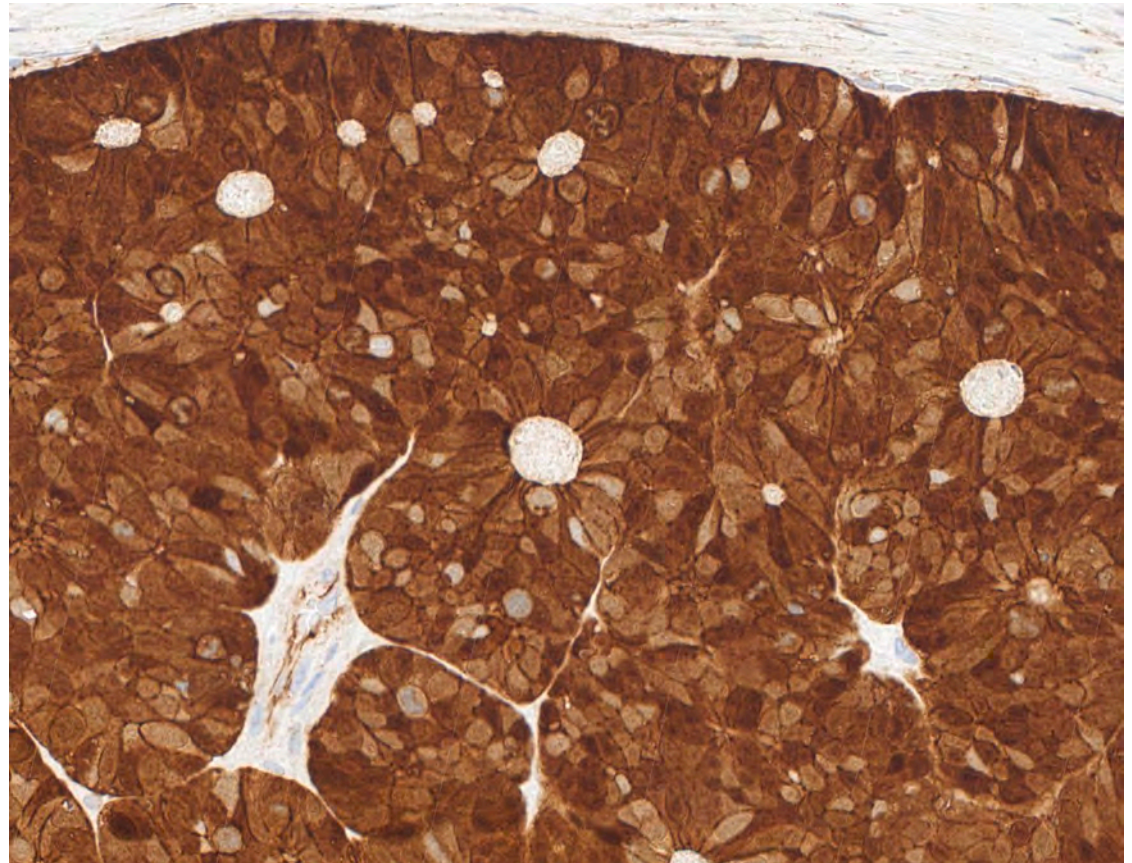
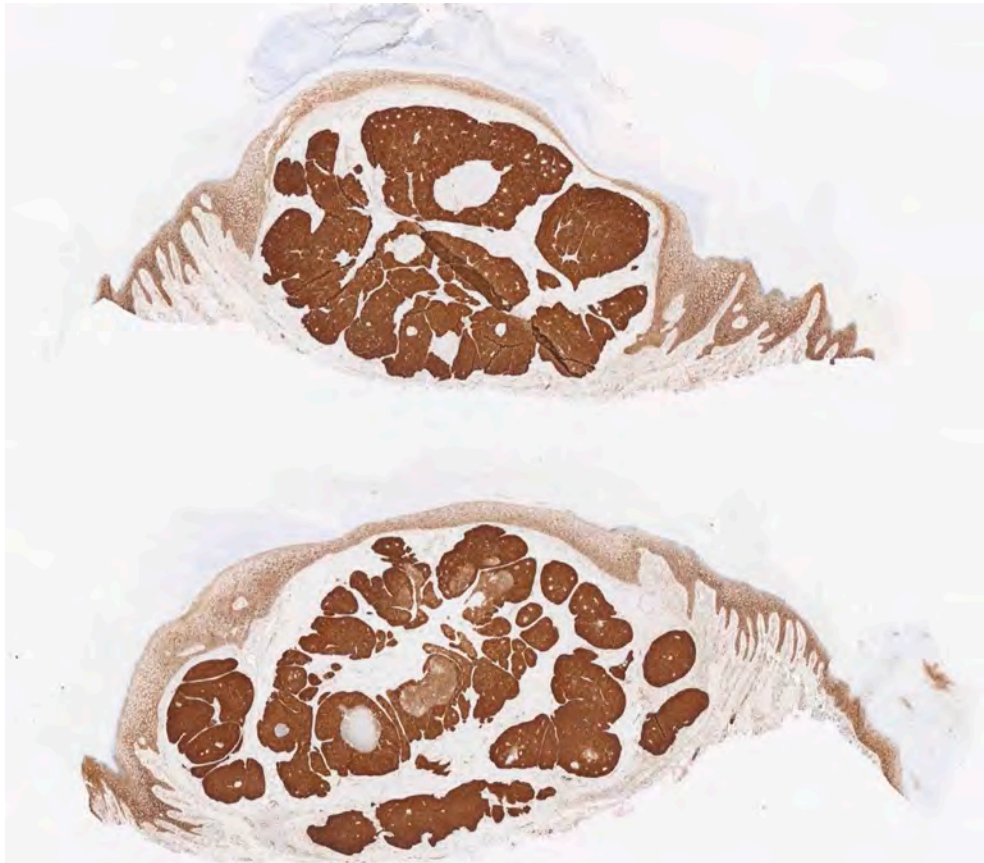


Summary of IHC Results



- Positive for
 - EMA
 - Beta-catenin
 - CDX2
 - Synaptophysin
- Negative for
 - CK20
 - Ab3

IHC : Beta-Catenin



WNT-activated non-pilomatrical carcinoma

MODERN PATHOLOGY



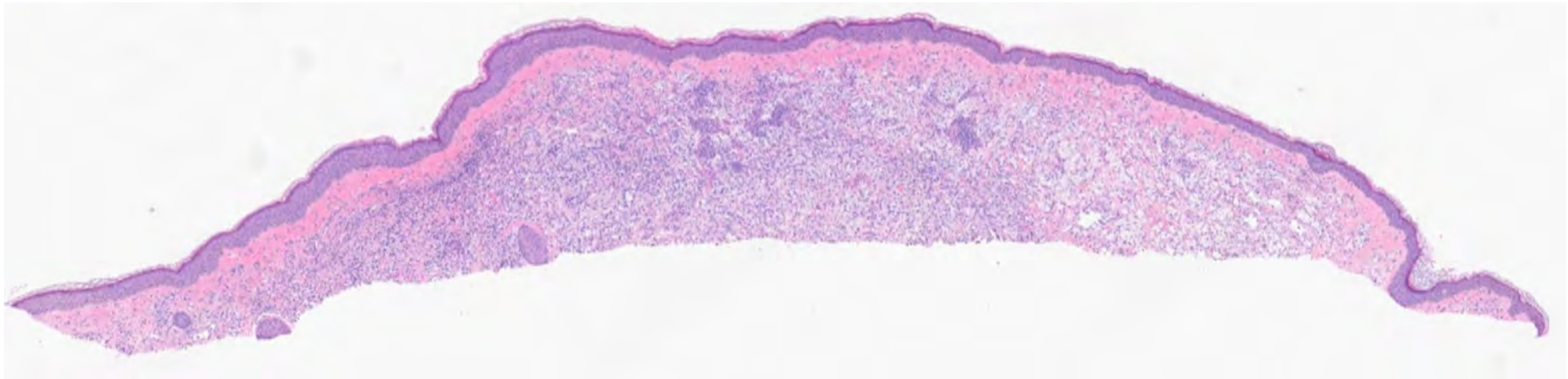
Journal homepage: <https://modernpathology.org/>

Research Article

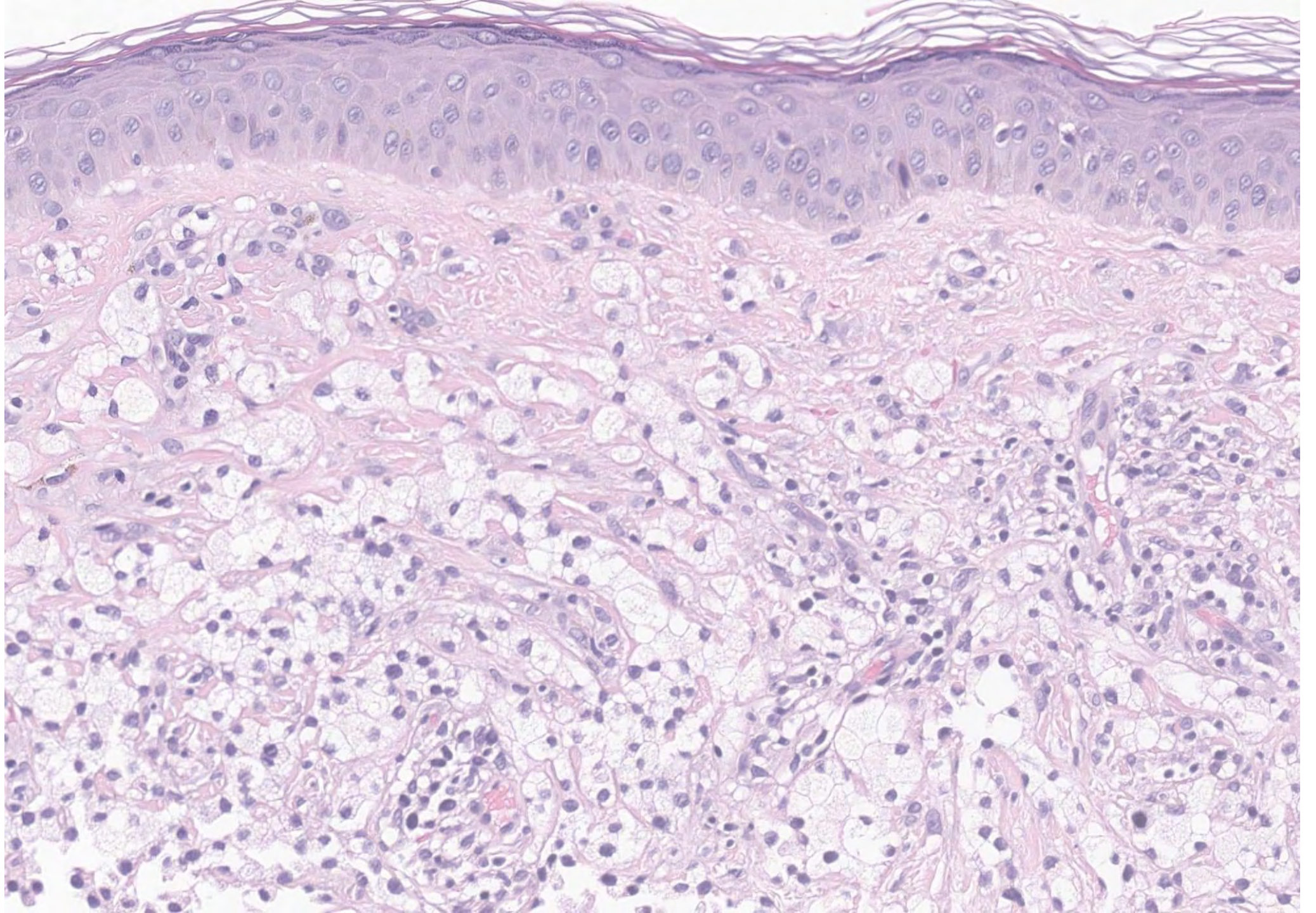
Wnt/ β -Catenin–Activated Nonpilomatrical Carcinoma of the Skin: A Case Series

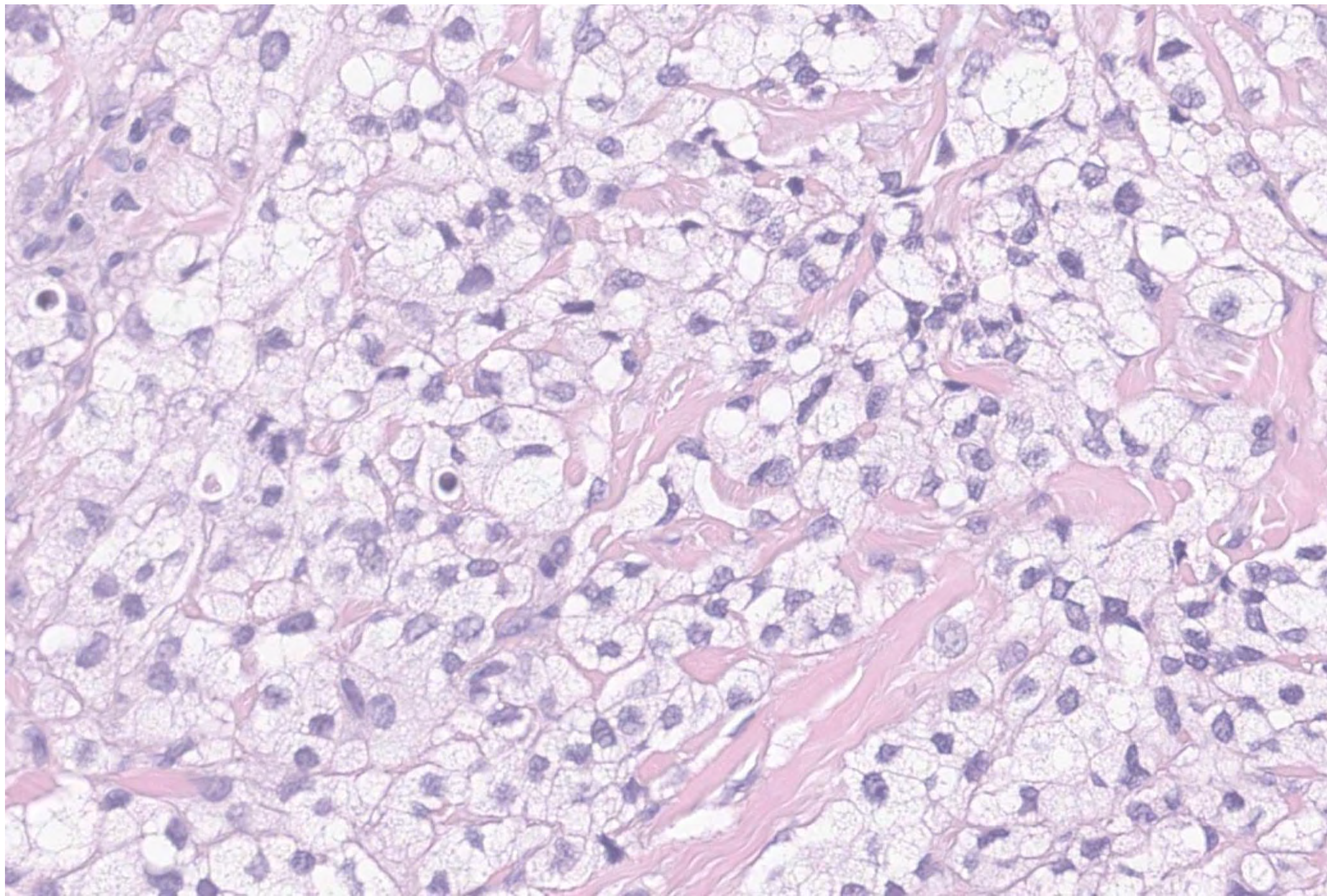
Thibault Kervarrec^{a,b,c,*}, Kuan Cheok Lei^d, Pierre Sohier^{c,e,f}, Nicolas Macagno^{c,g},
Marie-Laure Jullie^{c,h}, Eric Frouin^{c,i,j}, Keisuke Goto^{k,l,m,n}, Kohei Taniguchi^o,
Aymeric Hamard^a, Antoine Taillandier^a, Anne Tallet^p, Christine Bonenfant^p, Yusuf Sahinⁱ,
Fatoumata Barryⁱ, Saleem Taibjee^q, Kristof Cokelaere^r, Roland Houben^s, David Schrama^s,
Charlee Nardin^t, Francois Aubin^t, Laurent Doucet^u, Daniel Pissaloux^{v,w}, Franck Tirode^{v,w},
Arnaud de la Fouchardière^{v,w}, Brigitte Balme^x, Sara Laurent-Roussel^y, Jürgen C. Becker^{d,z},
Andreas von Deimling^{aa,bb}, Mahtab Samimi^{b,cc}, Bernard Cribier^{c,dd}, Maxime Battistella^{c,ee},
Eduardo Calonje^{ff}, Serge Guyétan^{a,b}

Case 12: What is Your Diagnosis?



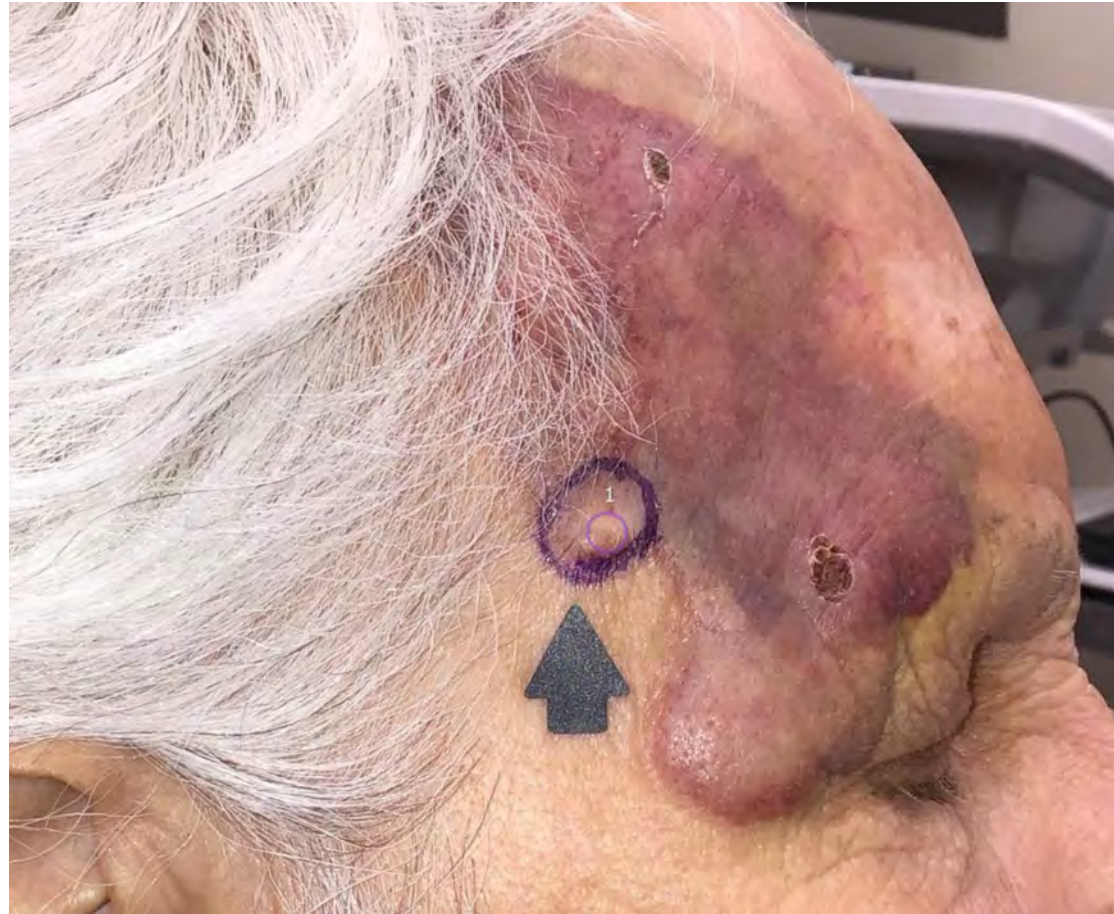82F with lesion on rt temple; shave bx



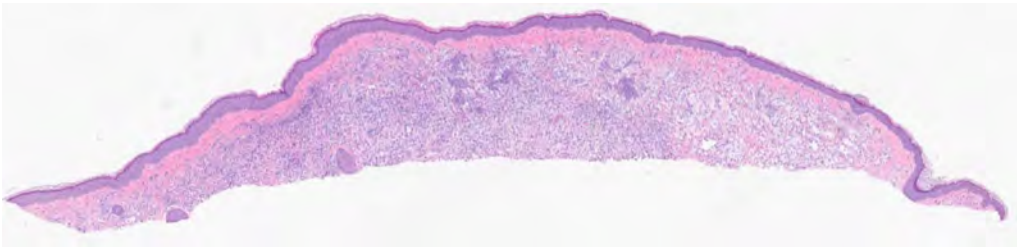


Clinical Presentation

- 82F
- Temple



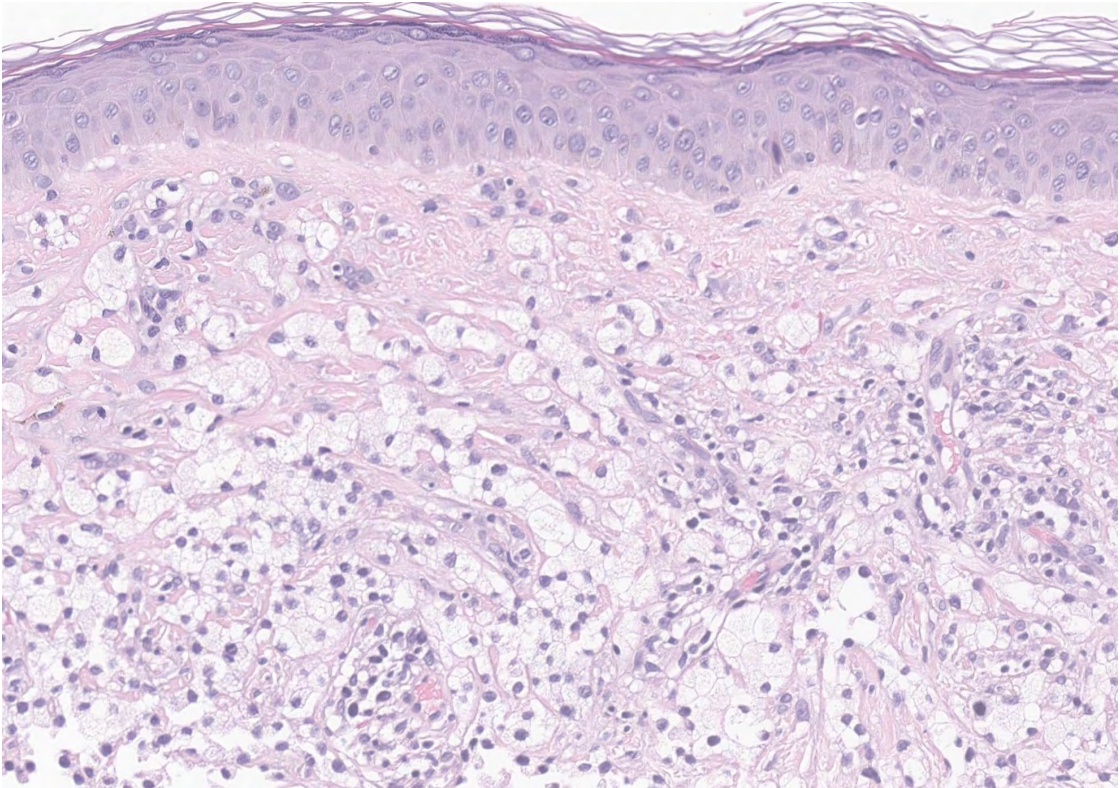
Diagnosis: Foamy Cell Angiosarcoma



CD31



ERG



Foamy Cell Angiosarcoma

J Cutan Pathol 2010; 37: 901–906
doi: 10.1111/j.1600-0560.2010.01512.x
John Wiley & Sons, Printed in Singapore

Cajal © 2010 John Wiley & Sons A/S
**Journal of
Cutaneous Pathology**

Foamy cell angiosarcoma: a rare and deceptively bland variant of cutaneous angiosarcoma

Cutaneous angiosarcoma can sometimes mimic other benign and malignant lesions, thereby presenting a difficult differential diagnosis. In the two cases of cutaneous angiosarcoma presented herein, extensive foamy cell alteration of tumor cells resembled a reactive xanthogranulomatous process. Foamy cell angiosarcoma is an unusual and deceptively benign morphologic variant of cutaneous angiosarcoma. Critical features for diagnosis include the presence of a deep, permeative, sometimes 'scaffolding' growth pattern and subtle areas of vascular formation.

Tatsas AD, Keedy VL, Florell SR, Simpson JF, Coffin CM, Kelley MC, Cates JMM. Foamy cell angiosarcoma: a rare and deceptively bland variant of cutaneous angiosarcoma.
J Cutan Pathol 2010; 37: 901–906. © 2010 John Wiley & Sons A/S.

Amy D. Tatsas¹, Vicki L. Keedy², Scott R. Florell³, Jean F. Simpson¹, Cheryl M. Coffin¹, Mark C. Kelley⁴ and Justin M. M. Cates¹

¹Department of Pathology and

²Division of Hematology/Oncology, Department of Medicine, Vanderbilt University Medical Center, Nashville, TN, USA,

³Department of Dermatology, University of Utah, Salt Lake City, UT, USA, and

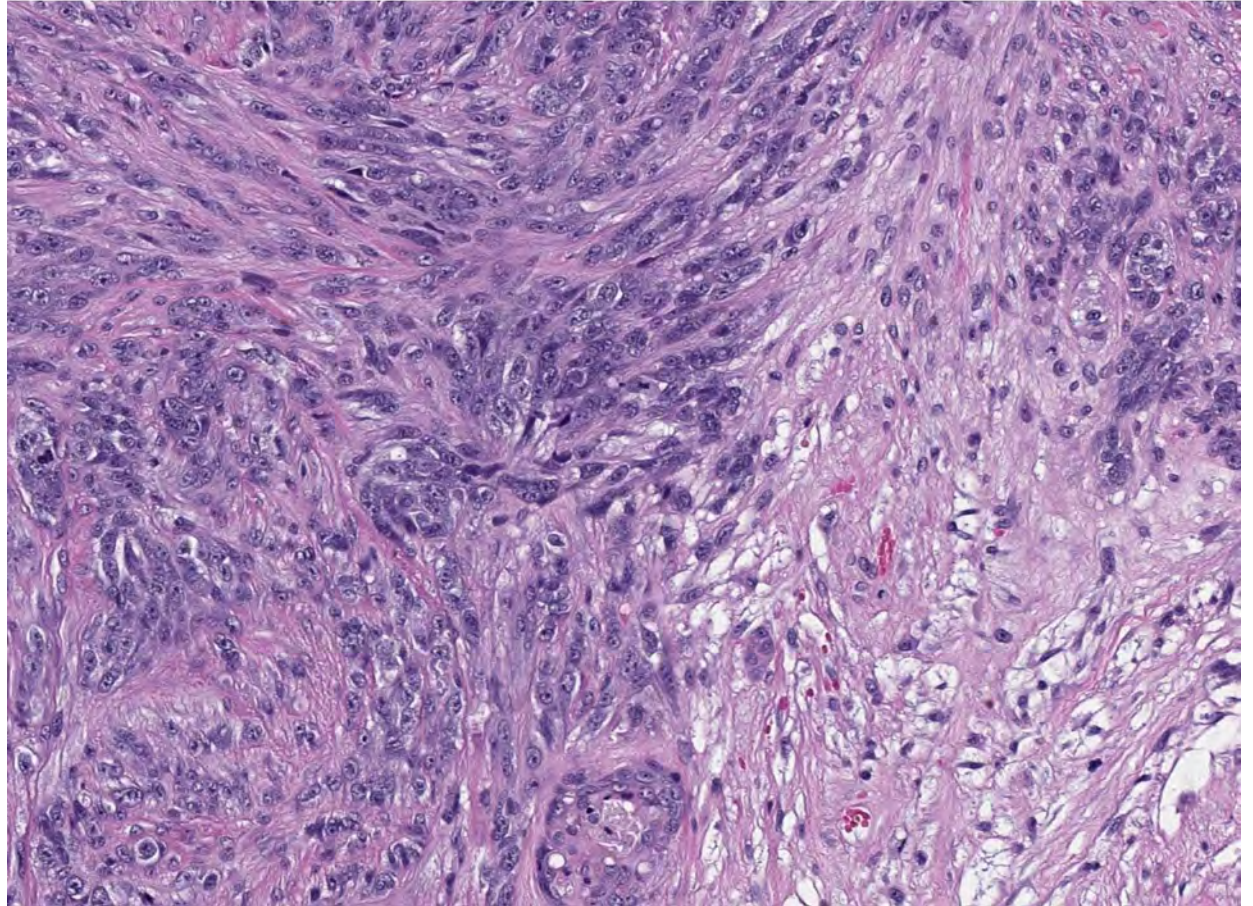
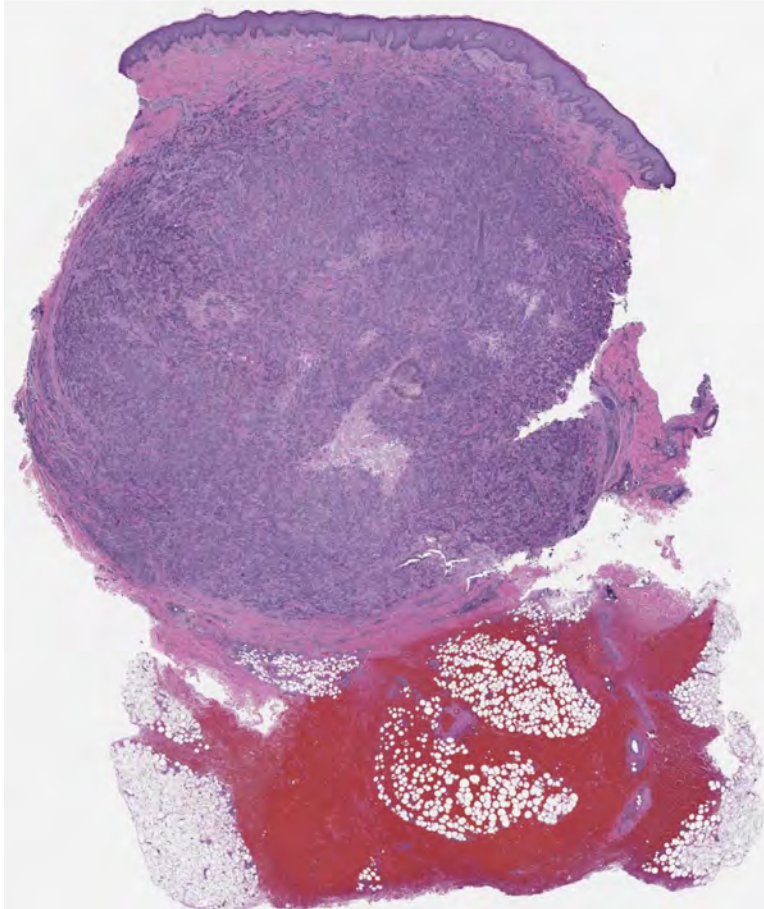
⁴Division of Surgical Oncology, Department of Surgery, Vanderbilt University Medical Center, Nashville, TN, USA

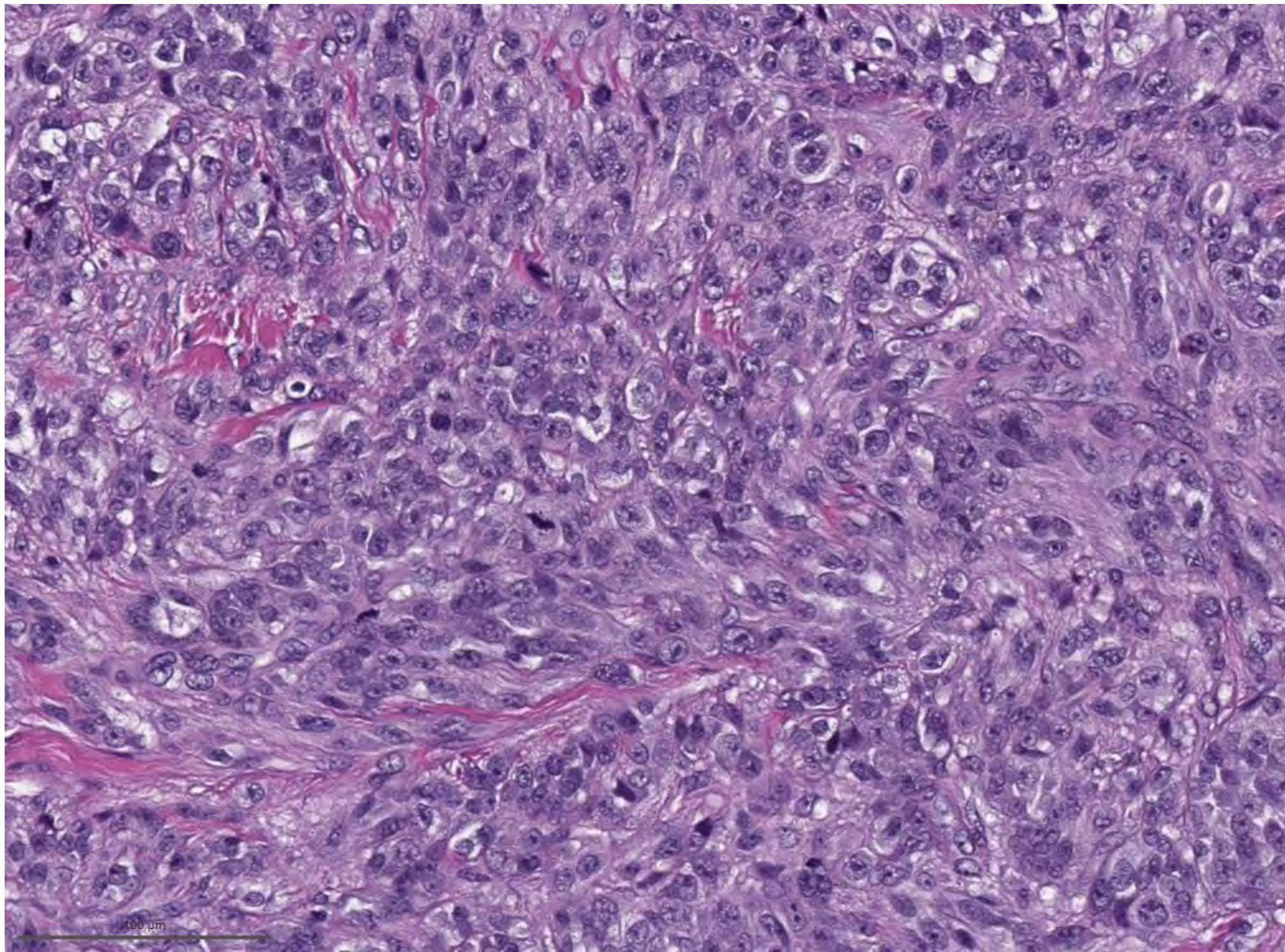
Armanda D. Tatsas, MD,
Department of Pathology, Vanderbilt University
Medical Center, 1161 21st Avenue, South
Nashville, TN 37232, USA
Tel: +1 615 322 2302
Fax: +1 615 343 7023
e-mail: armanda.tatsas@vanderbilt.edu

Accepted for publication December 12, 2009

- Rare variant of angiosarcoma
- Tumor cells with xanthomatous features
- Infiltrative growth
- Clinical context and IHC critical

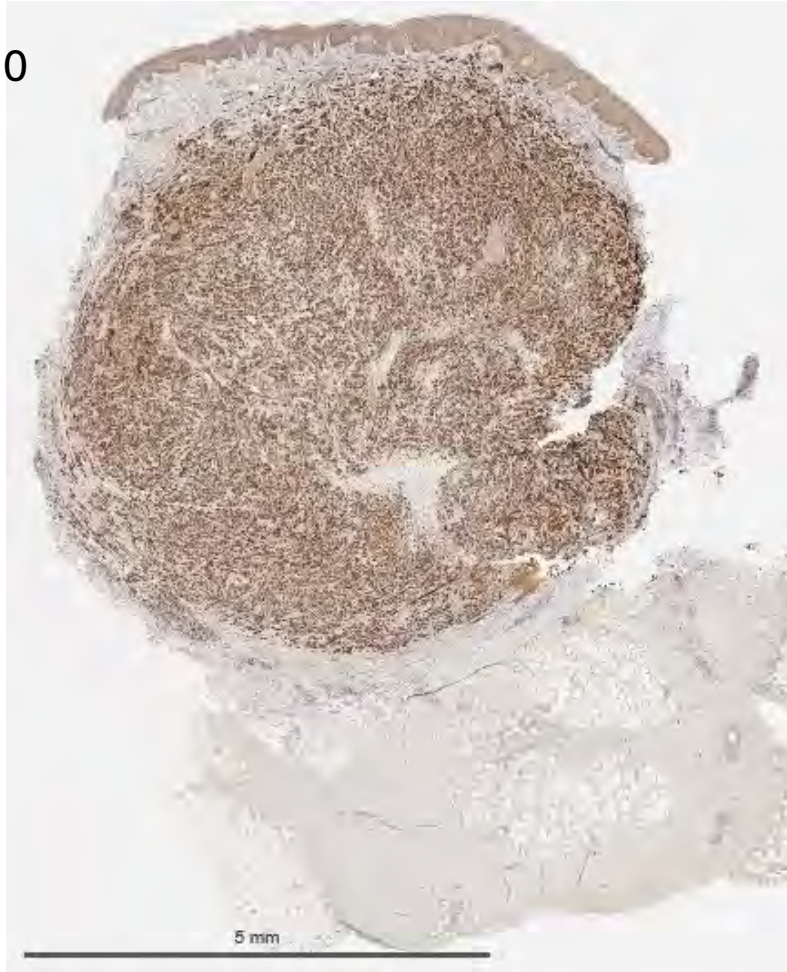
Case 13: 16 M, forearm; r/o DF





IHC

SOX10



- Immunohistochemistry

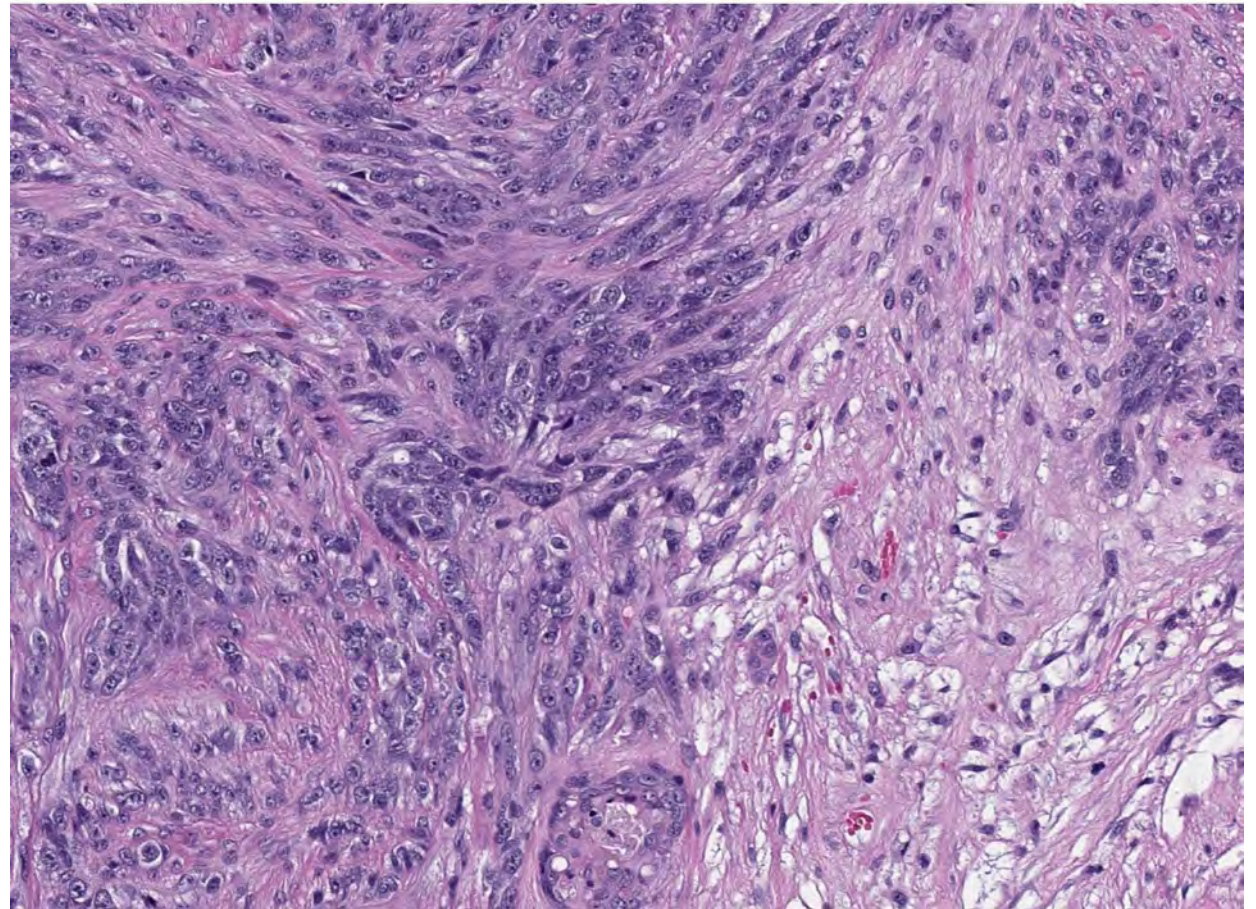
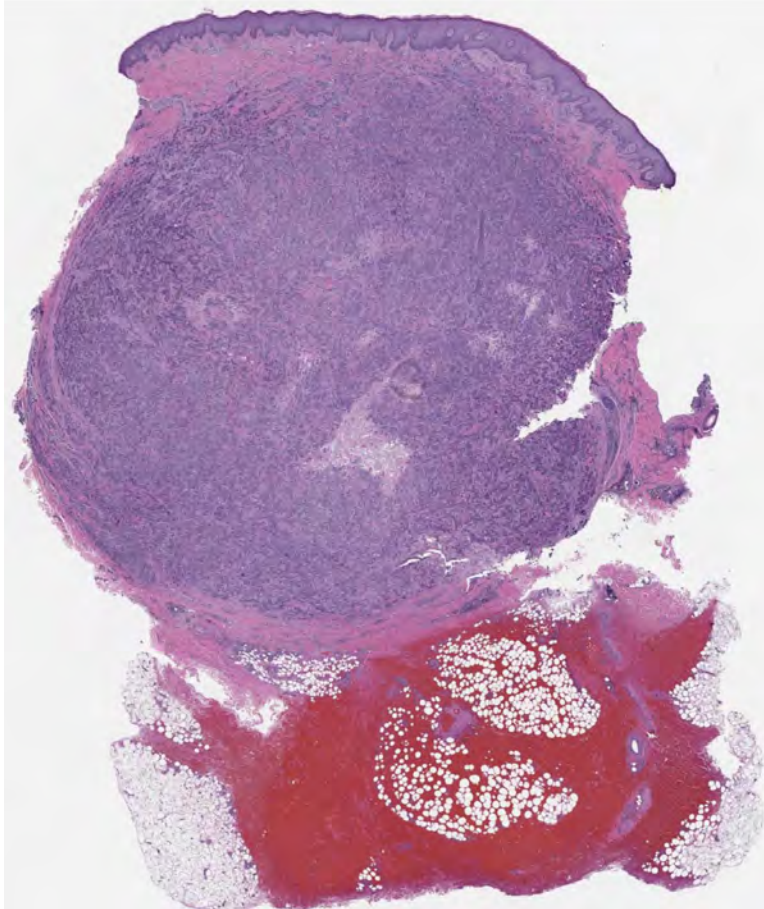
- Positive for

- S100, Sox10 (diffuse)
 - Melan-A, tyrosinase (focal)

- Negative for

- PRAME

Molecular Clue: CRTTC1::TRIM11 Fusion



Cutaneous Melanocytic Tumor With *CRTC1::TRIM11* Translocation

An Emerging Entity Analyzed in a Series of 41 Cases

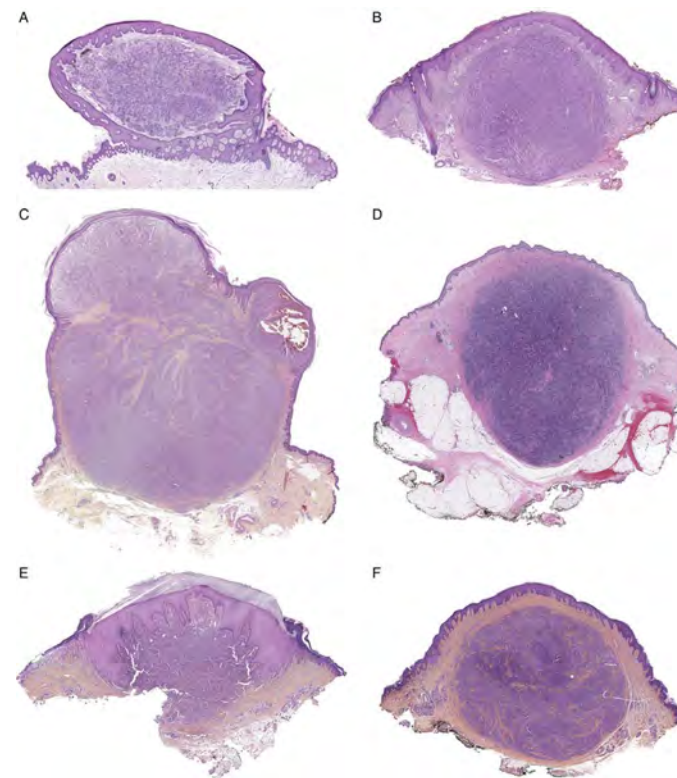
John Hanna, MD, PhD,* Jennifer S. Ko, MD, PhD,† Steven D. Billings, MD,† Felix Boivin, MSc,‡
Olivia Beaudoux, MD,§ Daniel Pissaloux, PhD,‡|| Franck Tirode, PhD,‡ Alvaro Laga, MD,*
Christopher D.M. Fletcher, MD,* and Arnaud de la Fouchardiere, MD, PhD‡||

TABLE 1. Clinicopathologic Characteristics of the Study Cohort

Characteristics	Total N = 41, n (%)
Patient age (y)	11-87
Median	44
Sex	
Male	18 (44)
Female	23 (56)
Tumor anatomic location	
Head	1 (2)
Trunk	8 (20)
Upper limb	15 (37)
Lower limb	11 (27)
Mucosal	2 (5)
Unknown	4 (10)
Clinical tumor size (mm)	5-13
Average (n = 10) (mm)	8.4

Of 22 cases with F/U

- 1 local recurrence
- 1 metastasis



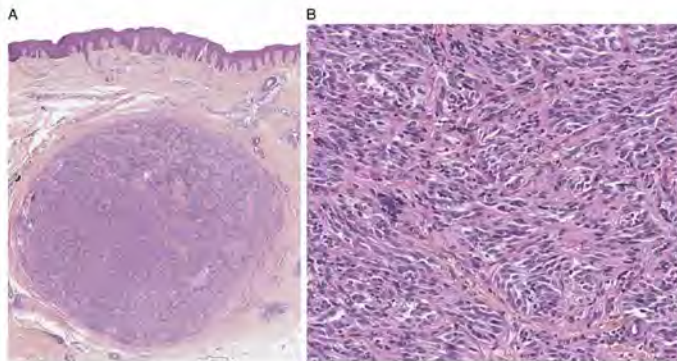
CRTC1::TRIM11 Tumor with Metastasis

Am J Surg Pathol 2018; 42:382-91

ORIGINAL ARTICLE

Cutaneous Melanocytoma With *CRTC1-TRIM11* Fusion Report of 5 Cases Resembling Clear Cell Sarcoma

Lucie Cellier, MD,* Emilie Perron, MD, MSc,*†‡ Daniel Pissaloux, PhD,*
Marie Karanian, MD,* Veronique Haddad, PharmD,* Laurent Alberti, PhD,*
and Arnaud de la Fouchardière, MD, PhD*



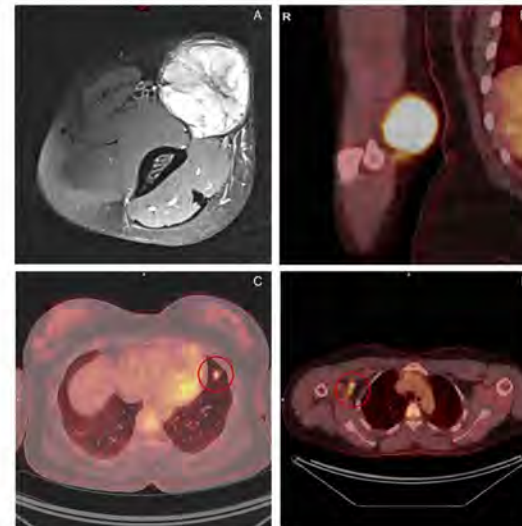
LETTER TO THE EDITOR

CRTC1-TRIM11 Fusion in a Case of Metastatic Clear Cell Sarcoma Are *CRTC1-TRIM11* Fusion-bearing Tumors Melanocytomas or Clear Cell Sarcomas?

To the Editor:

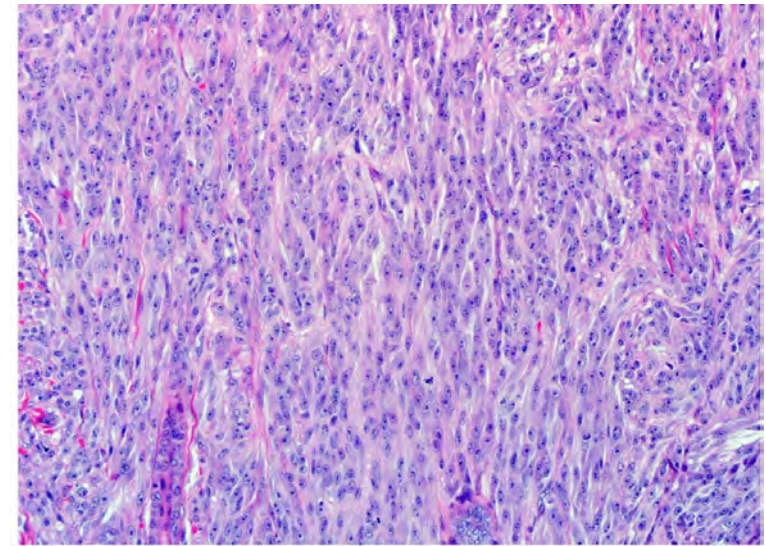
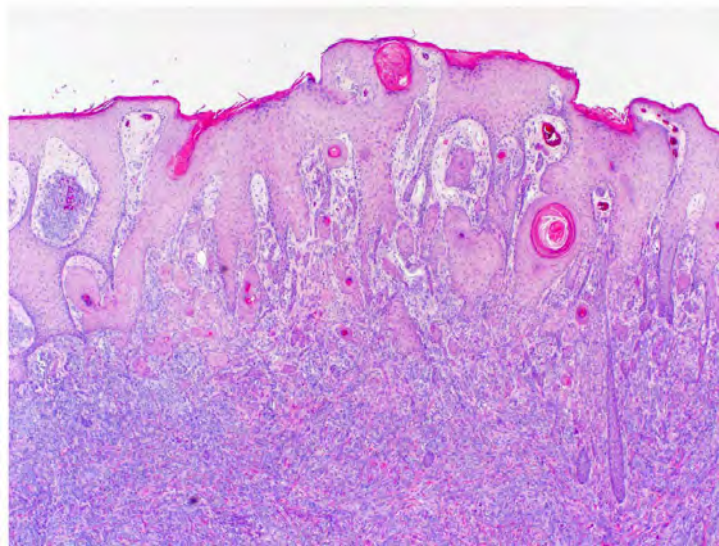
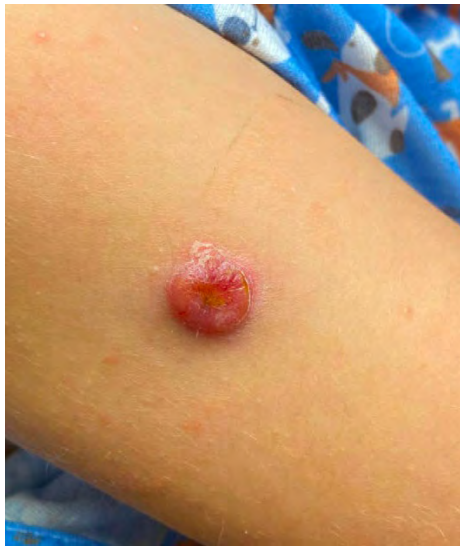We read with interest the article by Cellier and colleagues in the 2018 March issue of the *American Journal of Surgical Pathology* on the proposal of a new tumor entity named cutaneous melanocytoma with *CRTC1-TRIM11* fusion, which seems to have a favorable prognosis.¹ The authors reported 5 cases of unpigmented nodular dermal tumors, which harbored a previously undescribed invariable *CRTC1-TRIM11* fusion highlighted with RNA

sequencing (t(19;1)(p13;q42)). These tumors displayed a unique nodular pattern with dense fascicles and nests of unpigmented cells with medium to large atypical epithelioid and spindle cells, with constant expression of melanocytic markers (SOX10, MelanA, S100 protein, and HMB45), resembling dermal clear cell sarcoma (CCS). In some cases, necrosis and a high mitotic activity were observed. However, none of the 5 cases recurred during a median follow-up of 14 months (3 to 72 mo). On the basis



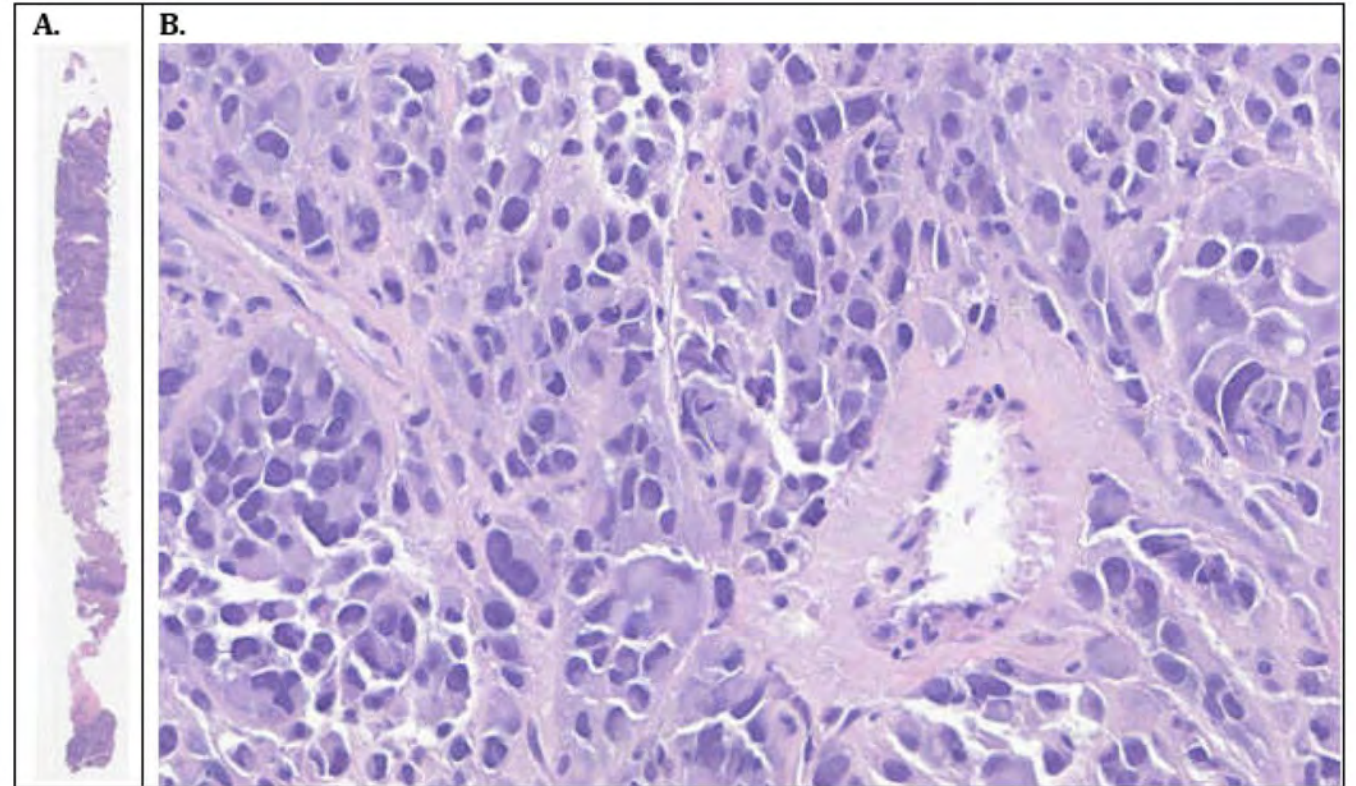
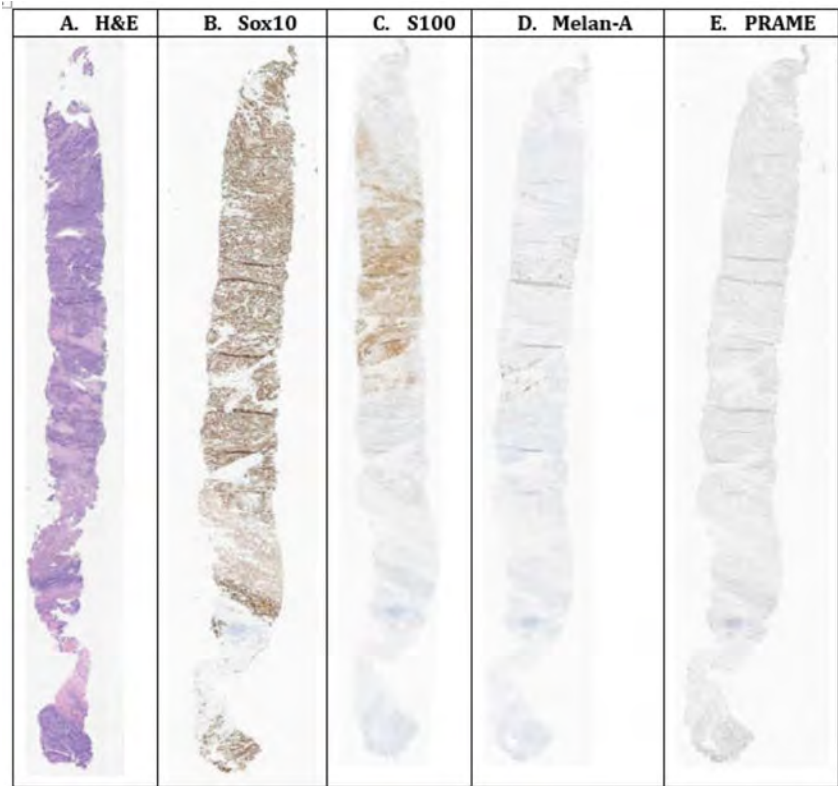
Cutaneous melanocytic tumor with *CRTC1::TRIM11* fusion and prominent epidermal involvement: A case report

Blake E. Vest MD¹ | Christina L. Harview MD¹ | Vincent Liu MD¹ |
Brian L. Swick MD¹ | Kristen G. Berrebi MD^{1,2} | Shantel Olivares BA³ |
Mary S. Stone MD¹ | Michael R. Sargen MD⁴ | Pedram Gerami MD³

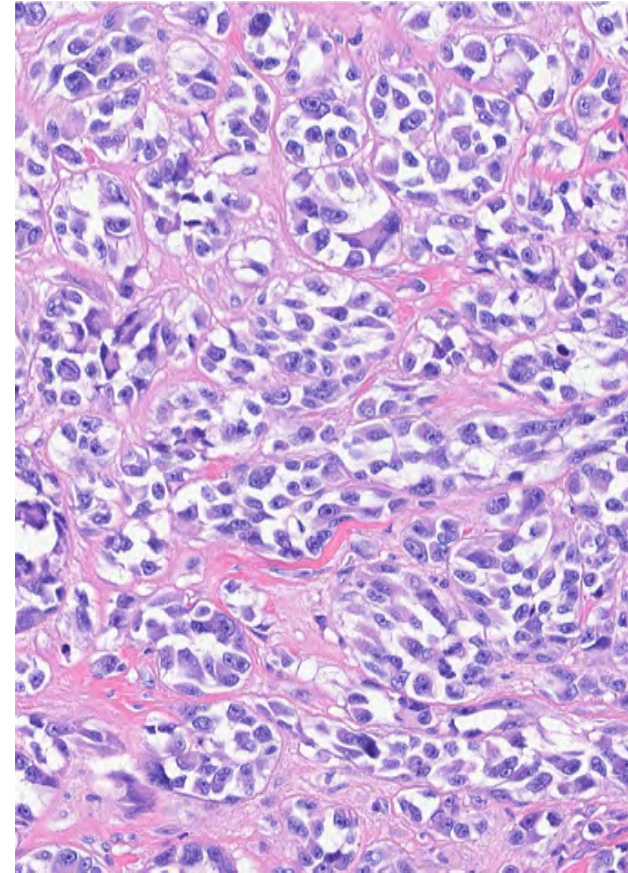
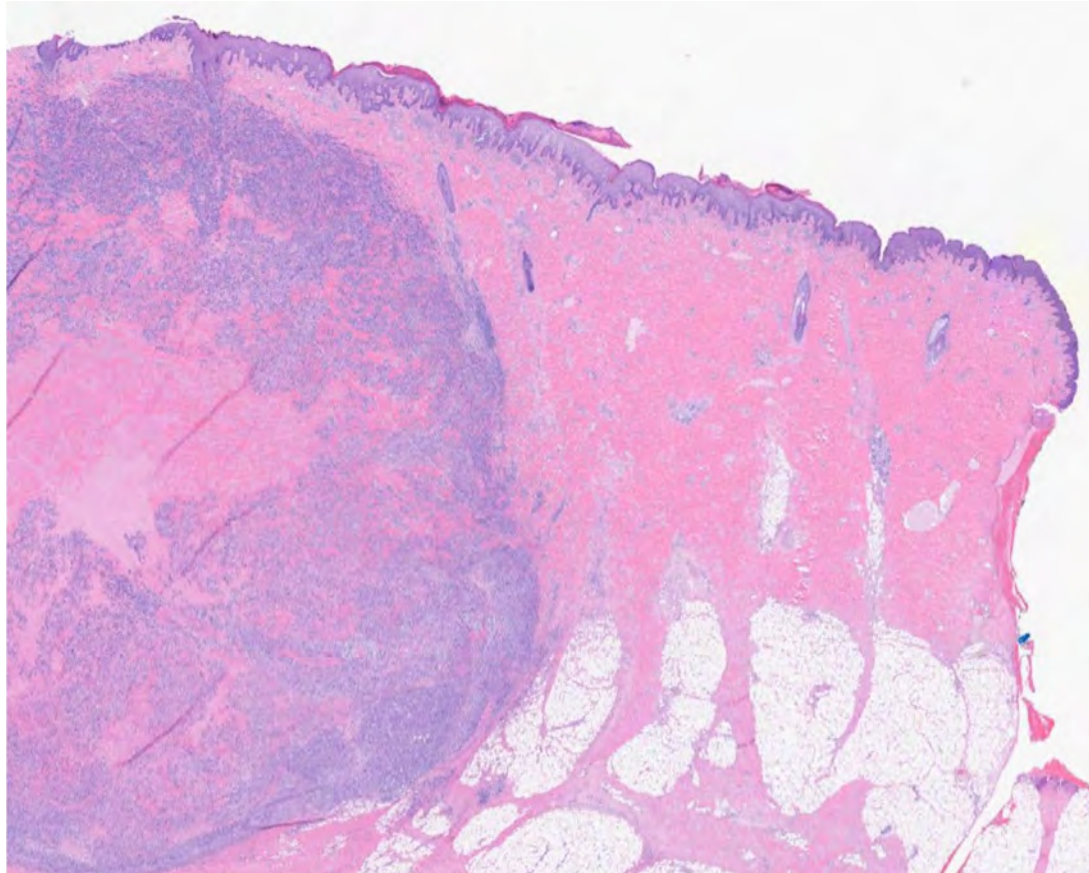


CRTC1::TRIM11 cutaneous tumor: An update with local recurrence and lung metastasis in a pediatric patient

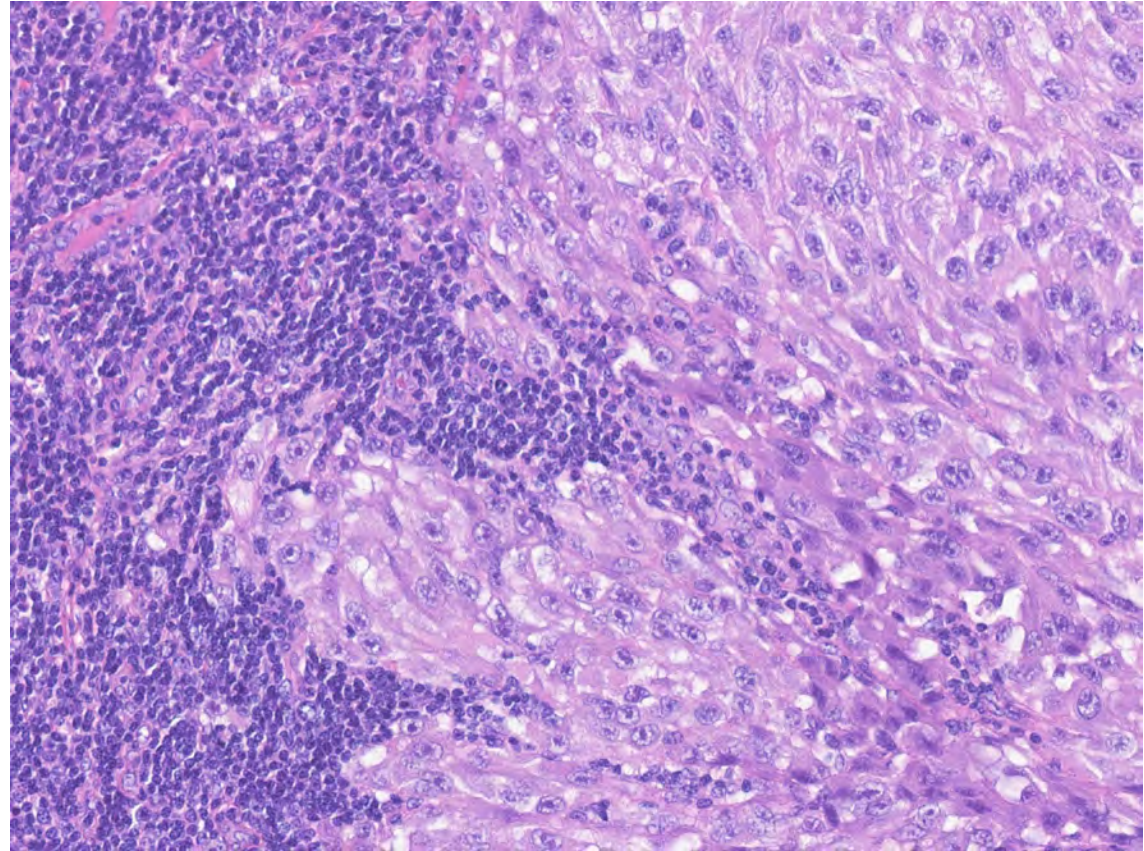
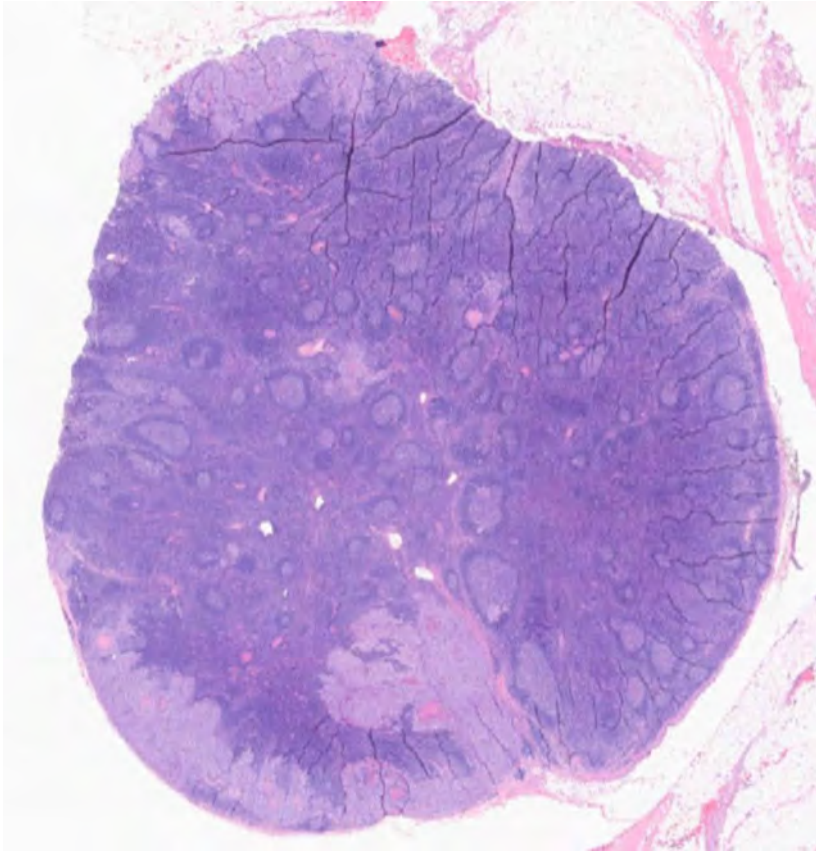
Case 14 : 17 F with shoulder mass



CRTC1::TRIM11 Tumor - Histopathology



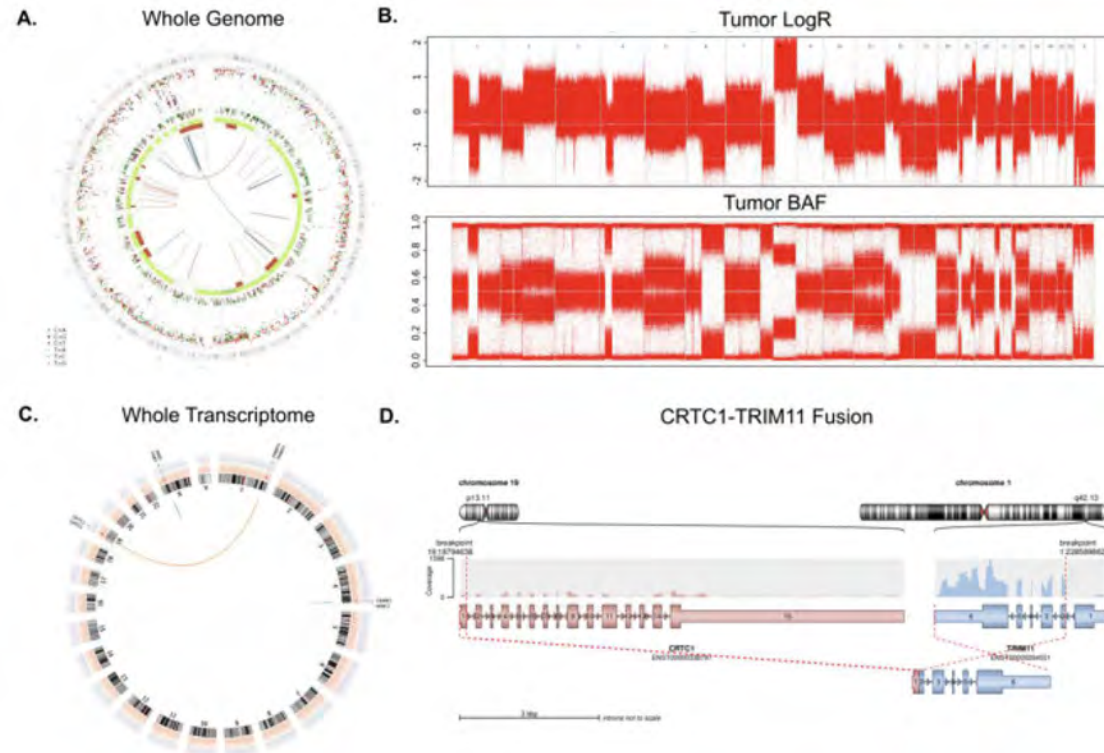
CRTC1::TRIM11 Tumor – LN Metastasis



CASE STUDY

Malignant *CRTC1::TRIM11* Cutaneous Tumor With Lethal Outcome: Histopathologic and Molecular Findings

Meghan E. Beatson¹ | James W. Smithy² | Dylan Domenico³ | Gunes Gundem³ | Elli Papaemmanouil³ | Andrea Moy¹ | Joyce M. Chen¹ | Melissa P. Pulitzer¹ | Charlotte Ariyan⁴ | Klaus J. Busam¹



Fusions:

- *CRTC1::TRIM11*
- *TENM3::WWC2*
- *TAB3::DMD*

Other aberrations:

- Del *BRAF*
- Copy gains of 8q

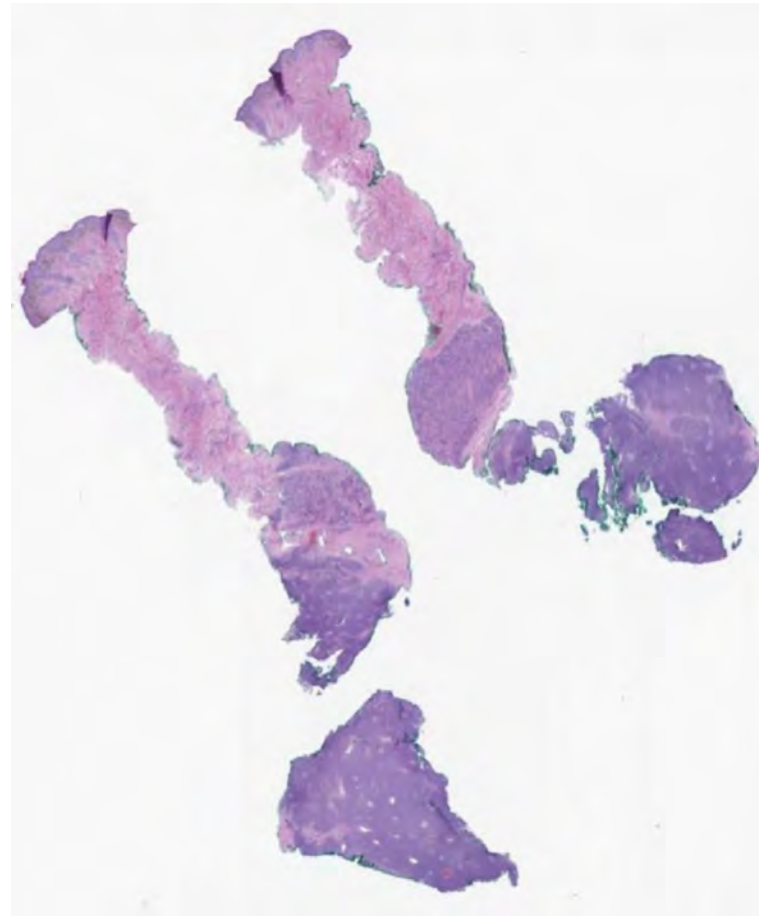
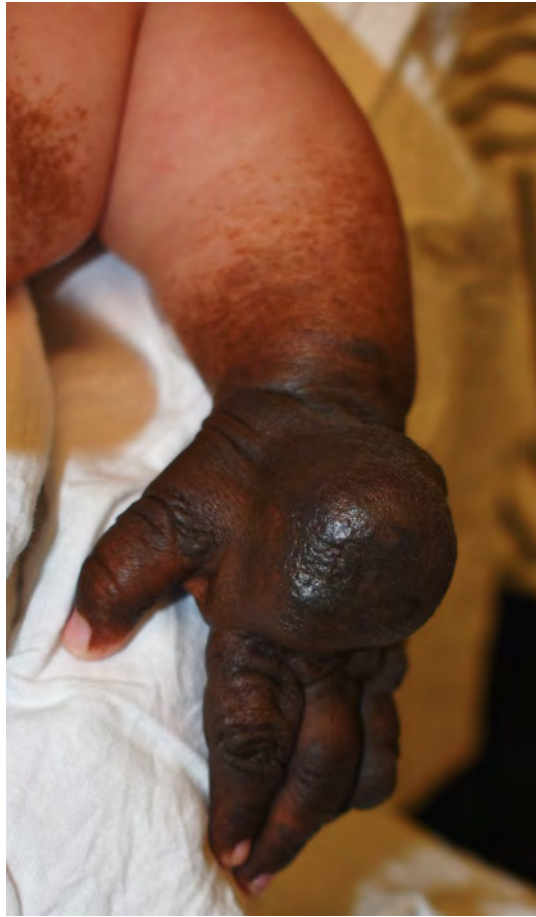Lessons

- CRTC1::TRIM11 tumors can be lethal
- More studies are needed to determine prognostic factors

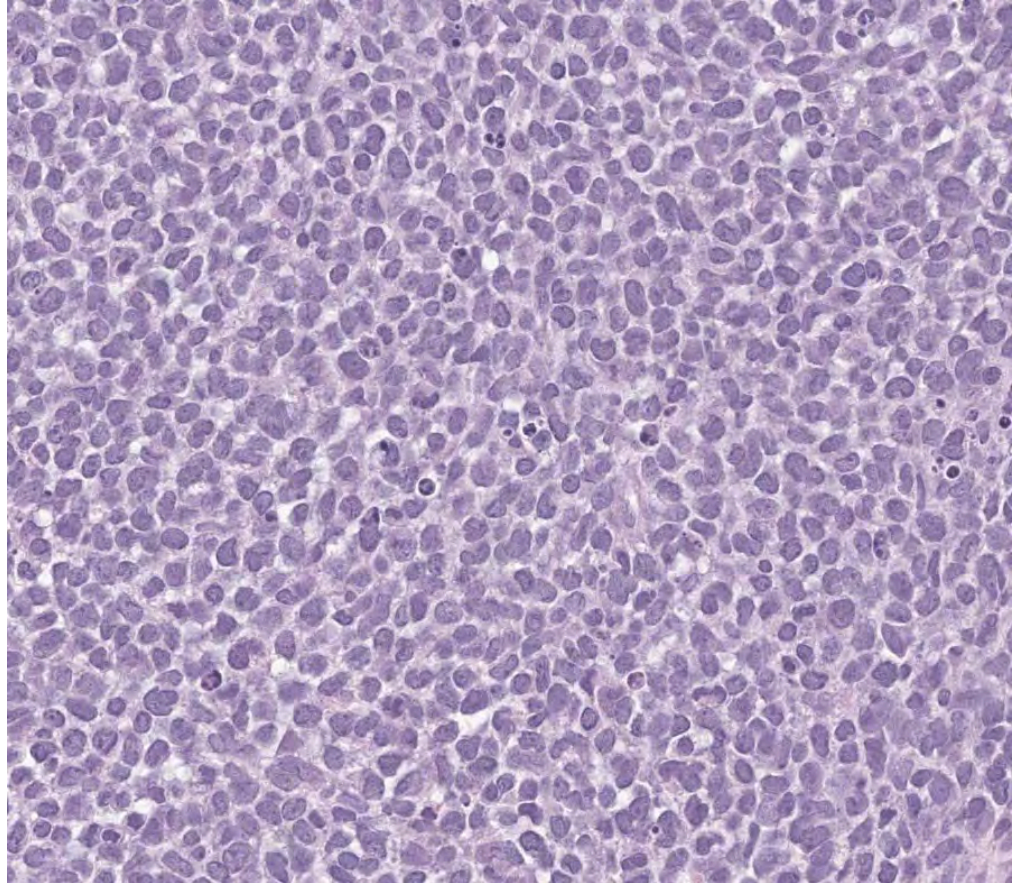
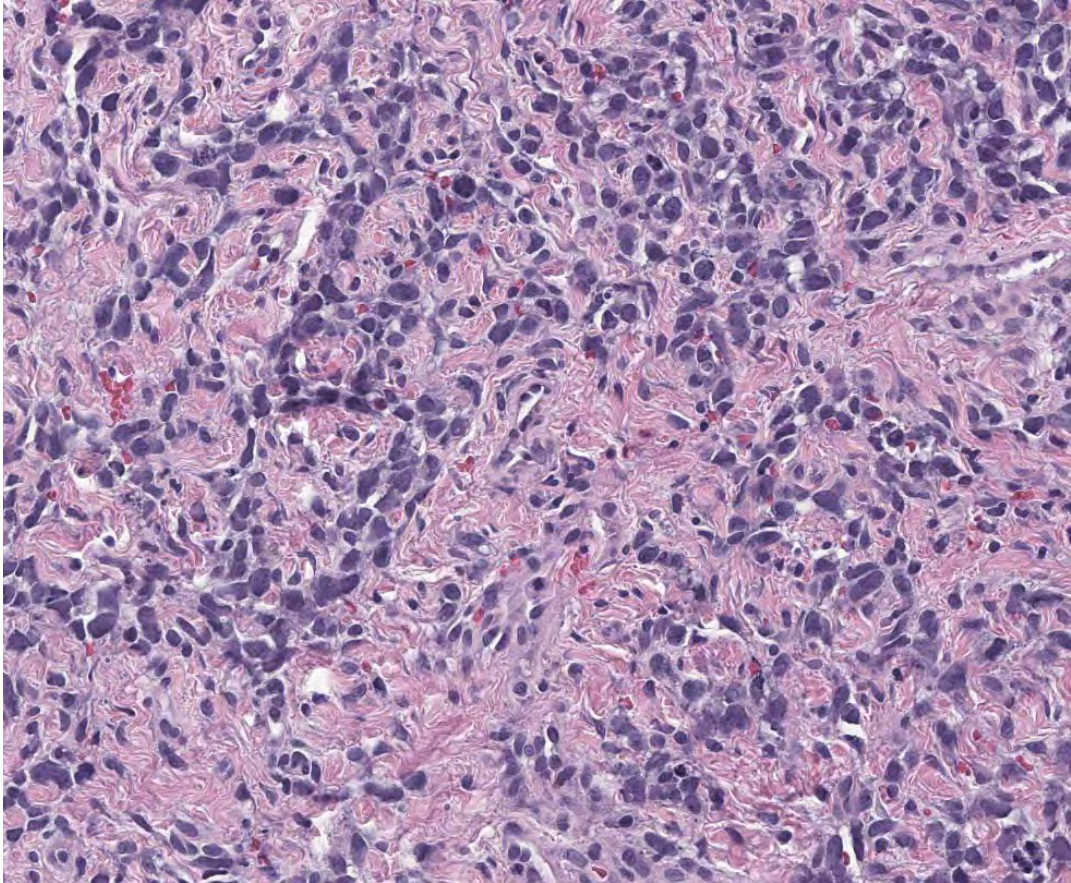
Case 15

Baby with a swollen hand

5 month-old boy with congenital melanocytic nevus and recent swelling of left arm



Small Cell Neoplasm

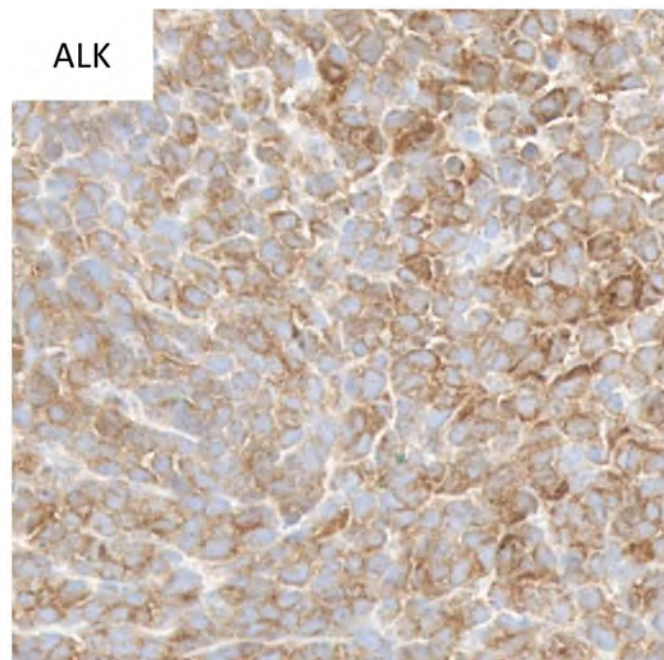
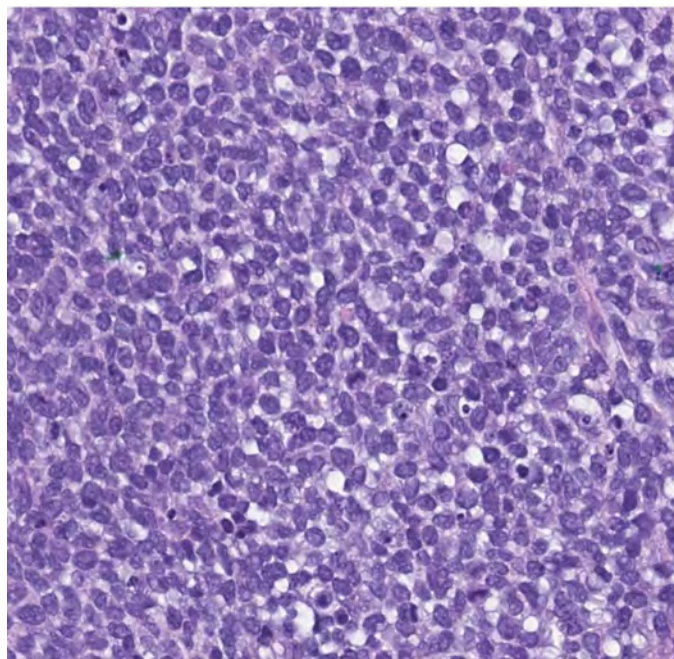


Evidence in support of malignancy

- Large growing clinical mass
- Undifferentiated small cell cytology with infiltrative growth
- Ancillary studies
 - Marked loss of H3K27me3
 - Segmental chromosomal aberrations

The tumor cells with ALK gene fusion

RNA Seq: ZEB2::ALK



Pediatric Melanoma with ALK-Fusion

Received: 14 March 2023 | Revised: 6 July 2023 | Accepted: 10 July 2023

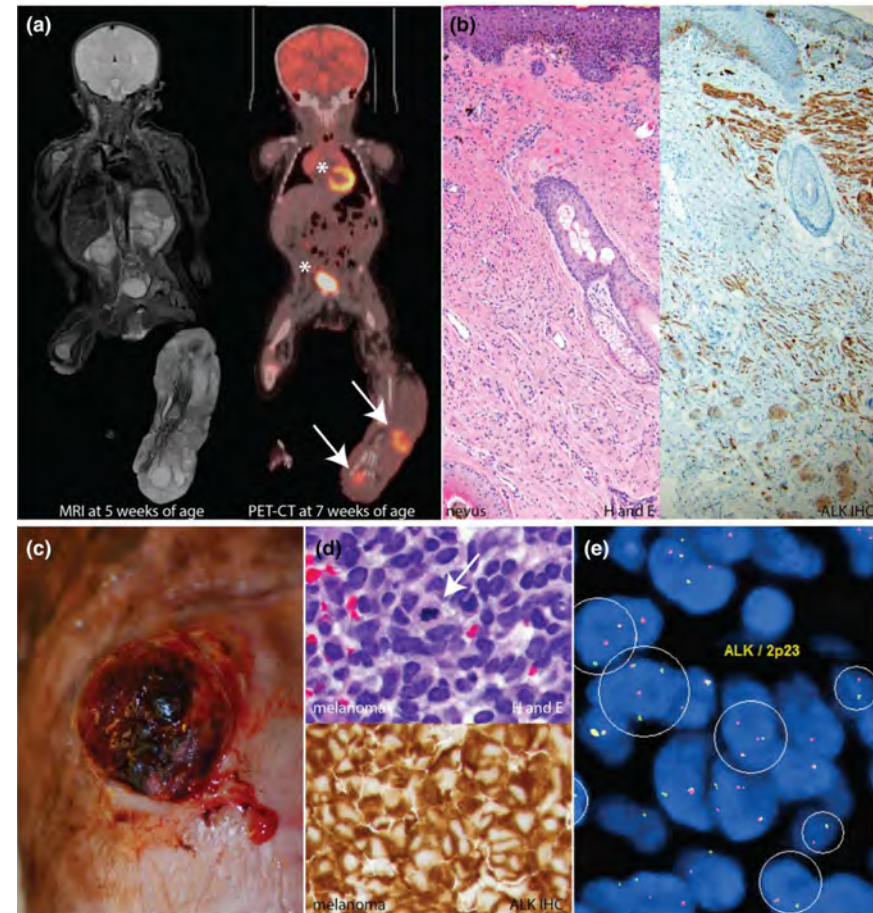
DOI: 10.1111/pcmr.13115

ORIGINAL ARTICLE

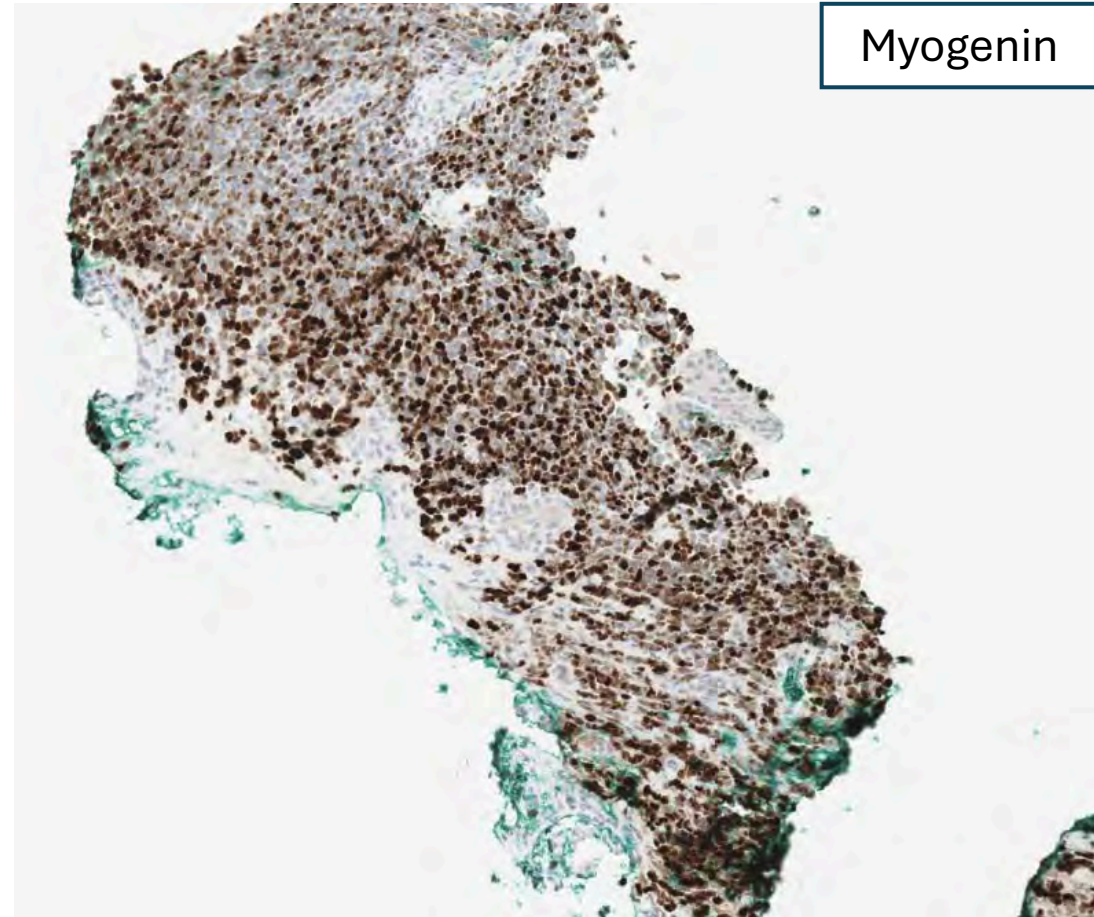
WILEY

Melanoma in infants, caused by a gene fusion involving the anaplastic lymphoma kinase (ALK)

Ifeoma U. Perkins¹ | Serena Y. Tan² | Timothy H. McCalmont^{3,4,5} | Pauline M. Chou⁶ |
Thaddeus W. Mully^{3,4} | Pedram Gerami^{6,7,8} | Jason H. Pomerantz^{9,10} |
Miguel Reyes-Múgica¹¹ | Daniel M. Balkin^{12,13} | Lacey L. Kruse^{7,8} | Benjamin Huang¹⁴ |
Jennifer L. Reichel⁸ | Noopur Gangopadhyay¹⁵ | Simon Chiosea¹¹ | Jared R. Green¹⁶ |
Sarah L. Chamlin^{7,8} | Ilona J. Frieden^{3,14} | Boris C. Bastian^{3,4} | Iwei Yeh^{3,4}



IHC: Expression of muscle markers

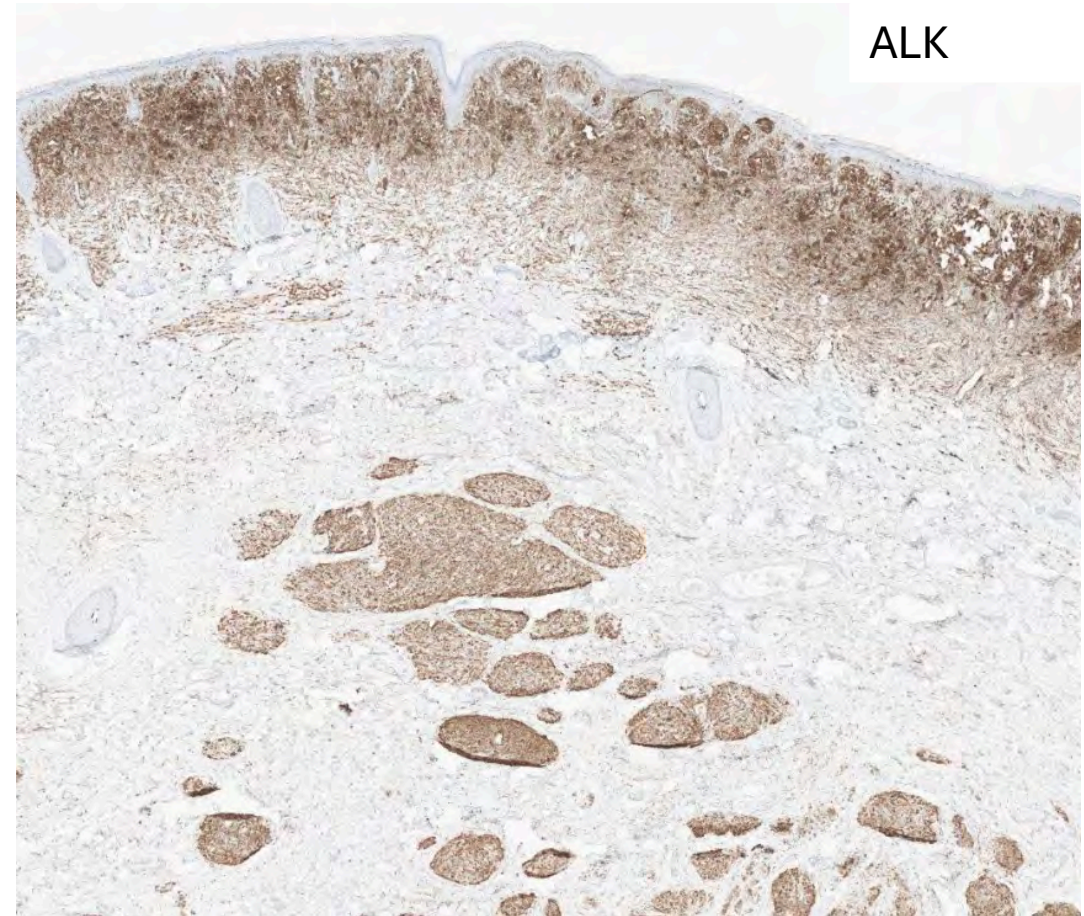
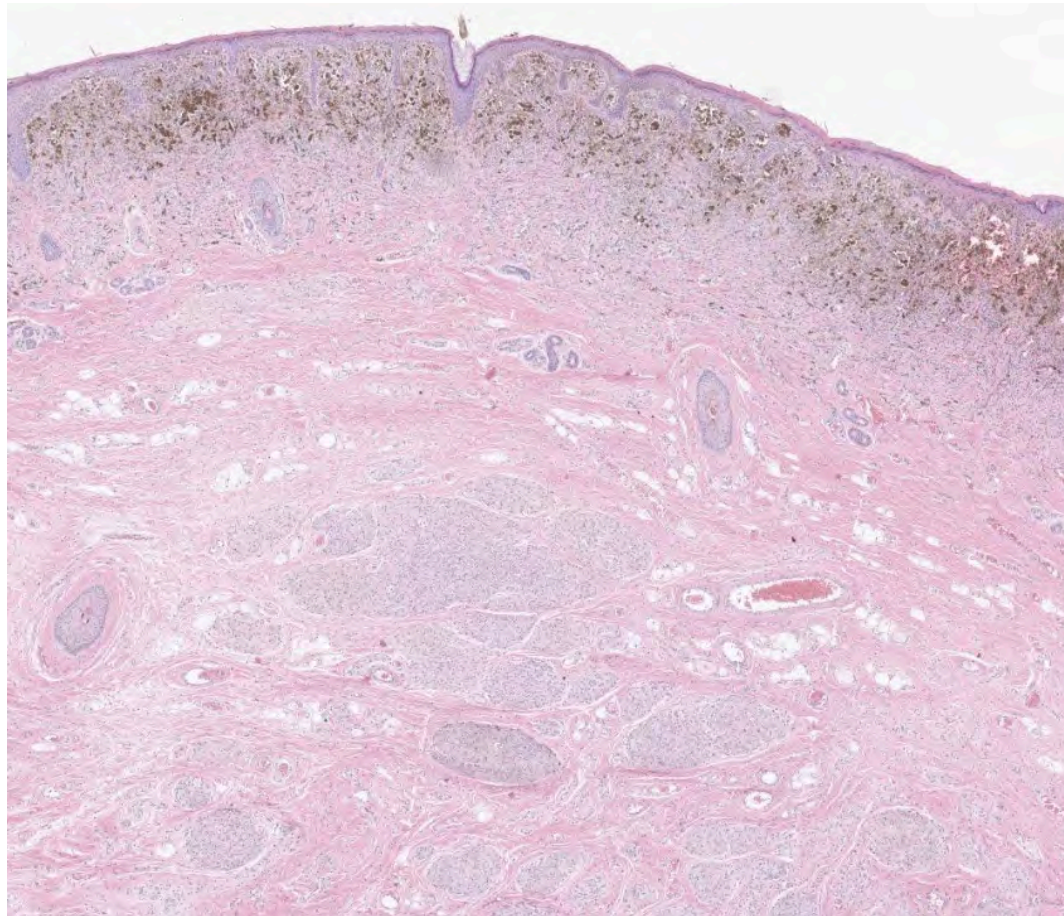


Diagnostic Interpretation

- A. Rhabdomyosarcoma at the site of a congenital nevus

- B. Melanoma with rhabdomyosarcomatous differentiation
(transdifferentiated melanoma)

Congenital Nevus with ALK Expression



Evidence in favor of transdifferentiated melanoma

- Malignancy arising in association with a melanocytic nevus
- Shared gene fusion (ZEB2::ALK) with melanocytic nevus

Summary

- Review of select cases with emphasis on sweat gland carcinomas
- Malignant tumors with melanocytic/mesenchymal differentiation
- Potential benefits of molecular studies

Acknowledgements

- Colleagues at MSKCC
- Colleagues elsewhere
- My family

busamk@mskcc.org

Thank You!

